

# Onychomycosis caused by *Curvularia lunata* in an immunocompetent host –A case report

Vijaya D.<sup>1\*</sup>, Vijaya S.<sup>2</sup>, Santhya S.T.<sup>3</sup>, Shakthi.R.<sup>4</sup>, Yashaswini. M.K.<sup>5</sup>

<sup>1</sup>Professor & Head of the Department, <sup>2</sup>Assistant Professor, <sup>3,4</sup>Postgraduate Student, Dept. of Microbiology, AIMS, B.G.Nagara, Karnataka, India.

<sup>5</sup>Tutor, Department of Microbiology, Raja Rajeshwari medical college & research centre, Bangalore, Karnataka, India.

## Corresponding author

E-mail: vijayadanand@rediffmail.com

## ABSTRACT:

**Introduction:** *Onychomycosis* is a fungal infection of nail caused by dermatophytes, yeasts or non-dermatophyte moulds. *Curvularia* species is a dematiaceous fungi. We are reporting a case of *Onychomycosis* caused by *Curvularia*, for its rarity.

**Case report:** A 45 year old female, agriculturist by occupation presented with black discolouration of left thumb nail since 6 months. KOH preparation of nail clipping showed dark pigmented septate hyphae with 3 to 4 celled conidia with transverse septa. Growth on Sabouraud's dextrose agar yielded *Curvularia lunata*. Same fungi was isolated on repeat culture. The patient was put on pulse therapy with Itraconazole.

**Key words:** *Onychomycosis*, *Curvularia lunata*, Itraconazole.

Access this article online	
Quick Response Code:	Website:
	www.innovativepublication.com
	DOI: 10.5958/2394-5478.2015.00025.4

## INTRODUCTION

Onychomycosis is a major public health problem with high incidence, associated morbidity and long lasting treatment with anti-fungal agents.<sup>1</sup> Onychomycosis comprises all fungal infections affecting the nail apparatus, i.e., nail matrix, nail plate, cuticle, mesenchymal tissue and nail folds. It accounts for up to 50% of nail disorders and 30% of all superficial fungal infections of the skin.<sup>2</sup>

In Onychomycosis, infected nails serve as a chronic reservoir of infection which can give rise to repeated mycotic infections of the skin.<sup>2</sup> Onychomycosis denotes any nail infection due to dermatophytes, non-dermatophytes moulds (NDM) or yeasts. NDM are filamentous fungi that are commonly found in nature as saprophytes and plant pathogens. Because NDM are not keratolytic unlike dermatophytes they only live on non-keratinised tissue, intercellular cement or must take advantage of previous keratin destruction by dermatophytes, trauma or other nail diseases. For this reason the incidence of Onychomycosis due to NDM is 1.45 to 17.6 %, which is lower than that caused by dermatophytes.<sup>1</sup>

*Curvularia* is one among the dematiaceous fungi. We are reporting a case of Onychomycosis caused by *Curvularia*, for its rarity.

## CASE HISTORY

A 45 year old female presented with black discolouration of left thumb nail since 6 months. She is an agriculturist by occupation, working in paddy fields. Black discolouration was first observed over the left thumb nail, gradually spreading to the other finger nails. There is no history of trauma, diabetes mellitus or other predisposing factors. On examination Patient is well built and oriented. Systemic examination was normal. On Local examination, nail was black, brittle, crumbled with longitudinal ridges. Toe nails were normal.

**Investigations:** Fasting Blood sugar level was 85 mg/dl. Nails clippings were collected and processed in the department of Microbiology.

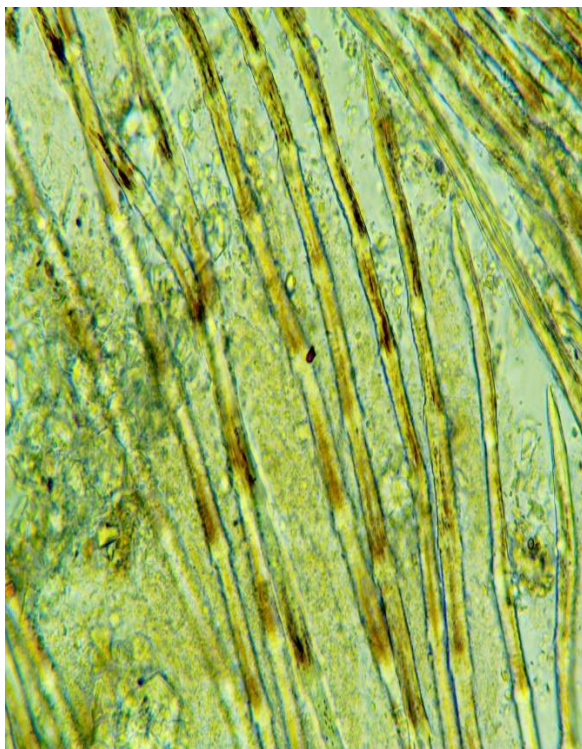
**Direct microscopy:** KOH preparation showed dark pigmented septate hyphae with 3 to 4 celled conidia with transverse septa. (fig 1).

**Culture:** Specimens were inoculated onto 2 sets of tubes

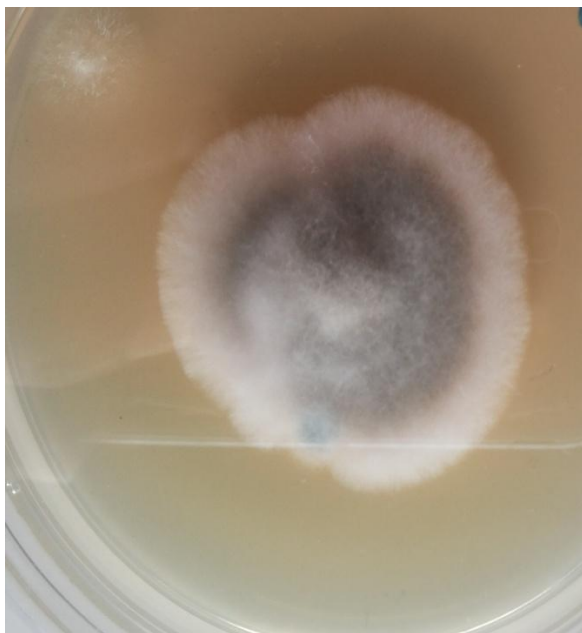
1. Sabouraud's dextrose agar
2. Sabouraud's dextrose agar with chloromycetin and actidione.

One set of tubes were incubated at room temperature and other at 37°C. Tubes incubated at room temperature and at 37°C showed greyish wooly colonies on 3<sup>rd</sup> day and blackish velvety colonies after a week (Fig 2), reverse showed brownish black discolouration. Lacto phenol cotton blue mount done by Slide culture technique showed septate branching pigmented hyphae with 3 to 4 celled conidia with transverse septa. The isolate was identified as *Curvularia lunata* (fig3).

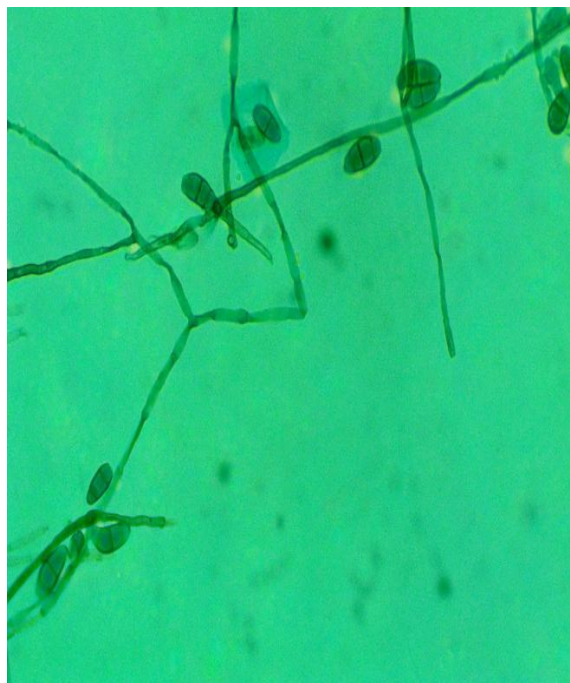
Repeat sample yielded same fungi. Patient was given pulse therapy with Itraconazole for a period of 3 months.



**Fig. 1: KOH mount of nail clipping showing pigmented hyphae.**



**Fig. 2: Growth on SDA**



**Fig. 3: Lactophenol Cotton Blue mount shows showed septate branching pigmented hyphae with 3 to 4 celled conidia with transverse septa.**

#### DISCUSSION

The incidence of onychomycosis in India is more because of warm and humid climate poverty, overcrowding, and lack of medical facilities contribute to high prevalence of the disease. Various studies have shown that the incidence of onychomycosis due to NDM has recently increased. Systemic infections like diabetes mellitus frequently cause onychomycosis. NDM isolated from the nail will be consider has pathogen , when the direct microscopy showed the presence of fungal elements and on follow up cultures yielding the same fungi as in the present case. Finger nails were more involved than toe nails.<sup>1</sup>

Onychomycosis was found to be commonest in agriculturists followed by labourers and house wives. In various studies thumb was commonest nail to involve.<sup>3</sup> Onychomycosis can occur at any age but it most commonly seen during 40-60 years of age and is unusual before puberty. Farmers are more prone for Onychomycosis, due to increased perspiration, a greater risk of occupation related trauma and exposure to soil saprophytes as seen in the present case. Treatment of onychomycosis requires more time than other fungi. NDM usually do not respond to antifungal elements.

Reports of human disease caused by *Curvularia lunata* are rare but include: endocarditis, brain abscess, skin infections, onychomycosis, keratitis, pneumonia, disseminated disease, mycetoma, allergic bronchopulmonary disease sinusitis.

In the present case patient was female, 45 years old, agriculturist by occupation which could be the cause for

infection. With the evidence of direct microscopy and repeated culture, we report *Curvularia lunata* as a causative agent in this case. Onychomycosis caused by *Curvularia* has been reported by others<sup>2,4-6</sup>.

#### REFERENCES

1. Lone R, Showkat HI, Bashir D, Khursheed S, Sarmast AH. Clinico-mycological pattern of onychomycosis A single center one year study in Kashmir-North India. *Eur J Gen Med* 2013;10(3):150-3.
2. Gupta M, Sharma NL, Kanga AK, Mahajan VK, Tegta GR. Onychomycosis: clinic-mycological study of 130 patients from Himachal Pradesh, India. *Indian J Dermatol Venereol Leprol* 2007; 73:389-92.
3. Veer P, Patwardhan NS, Damle AS. Study of onychomycosis: prevailing fungi and pattern of infection. *Ind J Med Microbiol* 2007;25(1):53-6.
4. Ramani R, Srinivas CR, Ramani A, Kumari TG, Shivananda PG. Molds in onychomycosis. *Int J Dermatol* 1993; 32(12):877-8.
5. Pukharambam PD, Devi KhR, Singh NB. Pattern of onychomycosis—a RIMS study. *J Commun Dis* 2011; 43(2):105-12.
6. Safdar A. *Curvularia*-favorable response to oral Itraconazole therapy in two patients with locally invasive phaeophomycosis. *Clin microbiol infect* 2003;9(12):1219-23.

**How to cite this article:** Vijaya D., Vijaya S., Santhya ST., Shakthi.R., Yashaswini. M.K. Onychomycosis caused by *Curvularia lunata* in an immunocompetent host –A case report. *Indian J Microbiol Res* 2015;2(4):249-251.