



Case Report

A fatal case of cupriavidus pauculus causing septicemia after duodenal perforation: Case report from university teaching hospital

Nishtha Singh¹, Amber Azim¹, Sheetal Verma^{1*}, Vimala Venkatesh¹, Armin Ahmad²

¹Dept. of Microbiology, King George Medical University, Lucknow, Uttar Pradesh, India

²Dept. of Critical Care Medicine, King George Medical University, Lucknow, Uttar Pradesh, India



ARTICLE INFO

Article history:

Received 29-03-2024

Accepted 01-04-2024

Available online 09-05-2024

Keywords:

Cupriavidus pauculus

Bacteremia

Bloodstream infection (BSI)

Antimicrobial resistance

ABSTRACT

Cupriavidus pauculus, a gram-negative bacterium is found ubiquitously in soil and water. It is very rare organism to cause human infection. Here we report a fatal case of septicaemia due to *C. pauculus* in a young female with duodenal perforation. Blood culture showed isolation of *C. pauculus* identified by MALDI-TOF-MS. The patient was treated with meropenem and piperacillin and tazobactam, but she died nine days after surgery. To our knowledge, this is the rare case report of *C. pauculus* causing septicemia after duodenal perforation.

This is an Open Access (OA) journal, and articles are distributed under the terms of the [Creative Commons Attribution-NonCommercial-ShareAlike 4.0 License](https://creativecommons.org/licenses/by-nc-sa/4.0/), which allows others to remix, tweak, and build upon the work non-commercially, as long as appropriate credit is given and the new creations are licensed under the identical terms.

For reprints contact: reprint@ipinnovative.com

1. Introduction

Cupriavidus pauculus formerly CDC group IV c-2 is a gram negative, rod shaped, non-sporing, and motile bacteria. It has catalase and oxidase activity and grows readily on the ordinary laboratory culture media at 35°C–37°C. It is found widely distributed in soil and water.¹ *Cupriavidus pauculus* (*C. pauculus*), formerly named *Wautersiapaucula*, is a aerobic, non-fermentative bacterium, part of the *Cupriavidus species*.² It was initially classified in the genus *Ralstonia*. It was re-classified in the genus *Wautersia* in 2004. In the same year, the genus was renamed as *Cupriavidus*.³ There are only few case reports of *C. pauculus* infection in immunocompromised patients and has associated with vascular access, use of parenteral nutrition or implantable cardiac defibrillator pocket infection. Also, reported in peritonitis, tenosynovitis, and meningitis, caused by this pathogen.^{4,5} Clinical disease caused by this organism ranges from abscess to septicemia. However, it is difficult to identify *C. pauculus* accurately by

conventional biochemical methods. Here we describe a fatal case of septicaemia due to *C. pauculus* in a young female with duodenal perforation. To the best of our knowledge, this is the interesting case of culture-proven bacteremia caused by multi-drug resistant *Cupriavidus pauculus*.

2. Case Report

An 18-year-old female presented at midnight to the emergency department of Surgery of King George's Medical University, Lucknow tertiary care referral hospital in North India, with the chief complaints of on and off vomiting and severe abdominal pain for the past 12 hours. On examination, the patient was conscious and alert, but ill-looking. Laboratory evaluation at the time of admission revealed hemoglobin - 9 g%, total leukocyte count - 14,100/cumm, neutrophil - 78.3%, lymphocyte - 9%, eosinophil - 2%, monocyte - 2%, basophil - 0%. Procalcitonin level (13.98 ng/mL) and CRP (26.30 mg/L) were elevated. Serum bilirubin total-8.5mg/dl, bilirubin, direct-6.10mg/dl and alkaline phosphatase- 1025.3IU/L were elevated. Blood was collected with complete

* Corresponding author.

E-mail address: nishsingh422@gmail.com (S. Verma).

aseptic precaution into aerobic and anaerobic adult blood culture bottle (BacT/ALERT/3D; bio-Merieux, Marcy l'Etoile, France). She underwent emergency exploratory laparotomy which revealed duodenal perforation and peritonitis. Perforation was sutured and managed. During the surgery her SpO₂ decreased drastically and patient was intubated. Chest X-Ray after intubation showed cloudiness on both side. Post-operative chest computed tomography (CT) showed no significant finding (Figure 1). The patient was transferred to the Critical Care Unit of the hospital for further management. Aerobic culture bottle beeped positive sign of growth after 18 hours of incubation. The broth was then sub-cultured on 5% sheep blood agar and MacConkey agar. After overnight incubation, MacConkey agar showed growth of non-lactose fermenting colonies with regular borders, smooth consistency, dry appearance and non-pigmented were observed and on blood agar no haemolysis was observed (Figure 2 A,B)). Further identification was done MALDI-TOF MS using the VITEK MS system (bioMérieux). This isolate was identified as *Cupriavidus pauculus* with 99% probability. Simultaneously, antimicrobial susceptibility test was performed by VITEK Compact 2 system (bioMérieux) and the minimum inhibitory concentrations (MICs) and breakpoints were determined based on the recommendations of Clinical and Laboratory Standard Institute (CLSI). The organism was susceptible to piperacillin-tazobactam, meropenem, imipenem and levofloxacin. The strain was resistant to cefotaxime, ceftazidime, gentamicin, amikacin and aztreonam (Table 1).

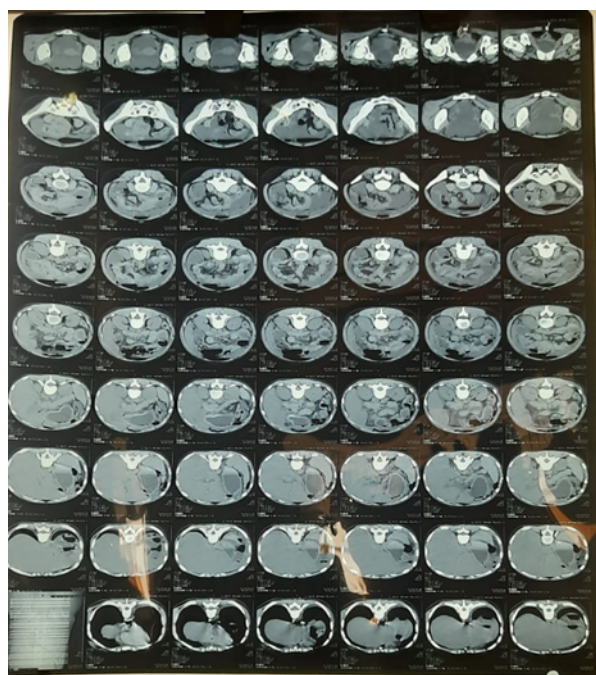


Figure 1: CT scan of abdomen: shows no significant abnormality

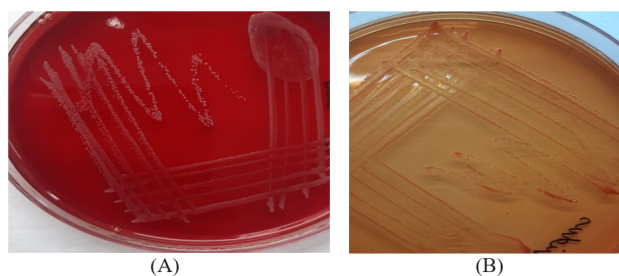


Figure 2: *Cupriavidus pauculus* colonies on (A) Blood agar: White transparent colonies; (B): MacConkey agar: Nonlactose fermenters, Oxidase positive colonies

Treatment - Based on culture and susceptibility reports patient was administered intravenous meropenem 1 gm IV every 8 hours for 7 days and piperacillin-tazobactam 4.5 gram for 5 days.

Outcome and follow up - Despite antibiotics the condition of the patient deteriorated and repeated blood cultures remained positive for *C. pauculus*. After seven days patient's clinical condition deteriorated and was pronounced dead at day nine of ICU admission due to multiple organ failure.

3. Discussion

Cupriavidus spp. are ubiquitous environmental organisms, mainly in water and plants. *C. pauculus* is the most important member of this family responsible for opportunistic infections and which can sometimes cause outbreaks.⁶ It is believed to cause nosocomial infections by the contamination of nebulization solution, ultrafiltrate water, thermos-regulator reservoir water, extracorporeal membrane oxygenation system (ECMO), tap water, hydrotherapy pools, and bottled mineral water.⁷ The genus *Cupriavidus* consists of Gram-negative, non-fermenting bacteria are usually environmental organisms found mainly in soil, water, and on plants. *C. pauculus* and *C. gilardii* can cause infections in patients with malignancies, transplants, and AIDS.⁸ Its infections in patients have been reported to cause urinary tract infections, bacteremia, pneumonia and meningitis.⁹ Nosocomial outbreaks have been reported on rare occasions due to contaminated water.¹⁰ There has been case series in which infections were related to the use of parenteral nutrition, therefore the TPN were dismissed in the ICU where the patient was admitted.¹¹ The timely and appropriate treatment of any infection depends on rapid and specific identification of causative microorganisms. The traditionally microbial identification by morphologic and biochemical characterization is cumbersome and difficult to interpret and thus causes delay in diagnosis which may lead to poor prognosis.¹² The MALDI-TOF MS, nanopore, 16S rRNA and next generation sequencing (NGS) technologies allows rapid and accurate detection of

Table 1: Results of blood culture and drug sensitivity test by vitek-ms

Result of Bacterial Blood Culture: <i>Cupriavidus pauculus</i>				Results of drug resistance			
Antibiotic (MIC)	Break point	Result	Sensitivity	Antibiotic (MIC)	Break point	Result	Sensitivity
Piperacillin	16-128	16		Gentamicin	4-16	16	R
Ceftazidime	8-32	>32	R	Cefotaxime	8-64	64	R
Cefepime	8-32	4		Aztreonam	8-32	>16	R
Imipenem	4-16	2		Meropenem	4-16	2	
Levofloxacin	2-8	2		Amikacin	16-64	>32	R

bacterial pathogens.¹³ The isolate identified in the present case was multidrug resistant and showed resistance to various group of antibiotics including imipenem, amikacin, gentamicin, and tobramycin which appears to be in concordance with previous studies.

The optimal therapeutic regimen for treating infections caused by *C. pauculus* remains unclear because of the limited data.¹⁴ There is need to study the intrinsic drug resistance mechanism in *C. pauculus*. Therefore, treatment must be based on antibiotic susceptibility results for better outcomes in future patients. An outbreak investigation was done and microbiological testing was done on water samples, environmental samples collected from the patient's room, ventilator, and water sink and intravenous fluids, however culture yielded no growth. The factors which suggest that *C. pauculus* was pathogen in the present case was isolation of the organism from several blood culture specimens.

An infection with *Cupriavidus* is overlooked in many cases due to the low index of suspicion and awareness among microbiologists and clinicians.¹⁵ Therefore, due consideration should be given to this organism to know the true magnitude of its infection in our country. The non-fermenters should be subjected to speciation as a part of routine microbiological work-up. To our best knowledge, this is the rare report of septicemia due to *C. pauculus* associated with duodenal perforation.

4. Conclusion

It appears that multidrug resistant *Cupriavidus* is an emerging rare pathogen in hospitalized patients. Clinicians and microbiologist needs to be vigilant. Early diagnosis and management is crucial to improve the outcome. An appropriate blood culture and automated platforms may help search for the potential pathogen timely for adequate treatment and outcome.

5. Source of Funding

None.

6. Conflict of Interest

None.

References

- Checucci A, Perrin E, Bazzicalupo M, Mengoni A. Genomic diversity and evolution of rhizobia. In: Das S, Dash HR, editors. *Microbial Diversity in the Genomic Era*. Academic Press; 2019. p. 37–46.
- Vandamme P, Coenye T. Taxonomy of the genus *Cupriavidus*: a tale of lost and found. *Int J Syst Evol Microbiol*. 2004;54(6):2285–9.
- Vandamme P, Coenye T. Taxonomy of the genus *Cupriavidus*: a tale of lost and found. *Int J Syst Evol Microbiol*. 2004;54(Pt 6):2285–9.
- Yabuuchi E, Kosako Y, Yano I, Hotta H, Nishiuchi Y. Transfer of two Burkholderia and an Alcaligenes species to *Ralstonia* gen. Nov.: Proposal of *Ralstonia pickettii* (Ralston, Palleroni and Doudoroff 1973) comb. Nov., *Ralstonia solanacearum* (Smith 1896) comb. Nov. and *Ralstonia eutropha* (Davis 1969) comb. Nov. *Microbiol Immunol*. 1995;39(11):897–904.
- Vandamme P, Goris J, Coenye T, Hoste B, Janssens D, Kersters K, et al. Assignment of Centers for Disease Control group IVC-2 to the genus *Ralstonia* as *Ralstonia paucula* sp. nov. *Int J Syst Bacteriol*. 1999;49(Pt 2):663–9.
- Baladallasat JM, Elkins C, Swyers L, Bannerman T, Pancholi P. Pseudo-outbreak of *Cupriaviduspauculus* infection at an outpatient clinic related to rinsing culturette swabs in tap water. *J Clin Microbiol*. 2010;48(7):2645–7.
- Stovall SH, Wisdom C, Mckamie W, Ware W, Dedman H, Fiser RT. Nosocomial transmission of *Cupriaviduspauculus* during extracorporeal membrane oxygenation. *ASAIO J*. 2010;56(5):486–7.
- Gomes I, Ferreira MM, Leitão J, Carvalho A. Multiresistant *Cupriavidus pauculus* infection in an immunocompromised elderly patient. *BMJ Case Rep*. 2021;14(7):e243328.
- Kobayashi T, Nakamura I, Fujita H, Tsukimori A, Sato A, Fukushima S, et al. First case report of infection due to *Cupriavidusgilardii* in a patient without immunodeficiency: a case report. *BMC Infect Dis*. 2016;16:493.
- Aydın B, Dilli D, Zenciroğlu A, Okumuş N, Ozkan S, Tanır G. A case of newborn with community acquired pneumonia caused by *Cupriaviduspauculus*. *Tuberk Toraks*. 2012;60(2):160–2.
- Taşbakan MS, Yamazhan T, Aydemir S, Bacakoğlu F. A case of ventilator-associated pneumonia caused by *Cupriavidus pauculus*. *Mikrobiyol Bul*. 2010;44(1):127–31.
- Duggal S, Gur R, Nayar R, Rongpharpi SR, Jain D, Gupta RK. *Cupriaviduspauculus* (*Ralstoniapaucula*) concomitant meningitis and septicemia in a neonate: first case report from India. *Indian J Med Microbiol*. 2013;31(4):405–9.
- Butler J, Kelly SD, Muddiman KJ, Besinis A, Upton M. Hospital sink traps as a potential source of the emerging multidrug-resistant pathogen *Cupriaviduspauculus*: characterization and draft genome sequence of strain MF1. *J Med Microbiol*. 2022;71(2):001501.
- Almasy E, Szederjesi J, Rad P, Georgescu A. A Fatal Case of Community Acquired *Cupriavidus Pauculus* Pneumonia. *J Crit Care Med (Targu Mures)*. 2016;2(4):201–4.
- Massip C, Coullaud-Gamel M, Gaudru C, Amoureux L, Doleans-Jordheim A, Hery-Arnaud G, et al. In vitro activity of 20 antibiotics

against *Cupriavidus* clinical strains. *J Antimicrob Chemother.* 2020;75(6):1654–8.

Vimala Venkatesh, Professor

Armin Ahmad, Additional Professor

Author biography

Nishtha Singh, Senior Resident

Amber Azim, Senior Resident

Sheetal Verma, Additional Professor

Cite this article: Singh N, Azim A, Verma S, Venkatesh V, Ahmad A. A fatal case of *Cupriavidus pauculus* causing septicemia after duodenal perforation: Case report from university teaching hospital. *Indian J Microbiol Res* 2024;11(1):57-60.