

Comparison of conventional Ziehl Neelsen staining with LED Fluorescent staining for pulmonary tuberculosis cases

Ashish Khanna^{1,*}, Poonam Sharma², Sarabjit Sharma³, Menka Khanna⁴

^{1,2,4}Associate Professor, ³Professor & HOD, Shri Guru Ram Das Institute of Medical Sciences & Research, Amritsar, Punjab

***Corresponding Author:**

Email: ashish_538@yahoo.co.in

Abstract

Introduction: According to WHO one third of world population has tuberculosis. Early diagnosis and appropriate treatment play an important role in combating the mortality and morbidity caused by tuberculosis. This study was undertaken to compare the efficacy of LED fluorescent microscopy and conventional Ziehl-Neelsen staining for the diagnosis of pulmonary tuberculosis.

Materials and methods: The study was conducted in the microbiology department of a tertiary care hospital in northern India by examining 234 consecutive sputum smear samples using LED as well conventional microscope.

Observations: Out of 234 sputum samples 62(26.5%) sputum samples were positive for AFB with Ziehl-Nelson and 84(35.9%) sputum samples were positive for with fluorescent microscopy.

Conclusion: It was found that LED based fluorescent microscopy is a better technique to identify M. tuberculosis with less time compared to the conventional microscope.

Keywords: Auramine O, Light emitting diode microscope, Tuberculosis, Ziehl-Neelsen staining

Introduction

Tuberculosis remains a public health problem in an endemic country like India. It has been more than hundred years since the discovery of *Mycobacterium tuberculosis* (1882) by Robert Koch, still we lack an effective and affordable diagnostic and treatment options. The situation is further worsening due to increase of HIV-TB co infection and drug resistant variants of *Mycobacterium tuberculosis*. The need of the hour is a good efficient affordable test which could diagnose the disease early so that effective treatment could be started immediately. *Mycobacterium tuberculosis* causes both pulmonary as well as extra pulmonary tuberculosis. Extra pulmonary sites can be bone and joint, lymph nodes, pleura, meninges, gastrointestinal tract, pericardium, genitourinary tract, peritoneum etc. India being an endemic country has high number of people having infection with *Mycobacterium tuberculosis* (about 40% of the Indian population is infected with tubercle bacilli). Majority of the population is having latent tuberculosis than active disease. According to World Health Organization (WHO) out of the 88 lakh cases of tuberculosis worldwide about 22 lakhs are found in India. Tuberculosis accounts for about 15 lakh deaths annually.^{1,2}

With the advancement in technology a large number of tests have been developed for the diagnosis of tuberculosis. But in an endemic country like India there is a dire need for a diagnostic techniques that is highly sensitive as well as affordable for the general poor population. Sputum smear microscopy is considered as the most reliable diagnostic test available even in areas having large number of cases and financial constraints. Fluorescent microscopy enhances

the diagnostic ability in sample having a low density of acid fast bacilli, which is at times missed by Ziehl-Neelsen (ZN) staining; Auramine O staining is advantageous over ZN staining as it is simpler, cost effective and can be visualized even at low magnifications than ZN(40x/100x). ZN staining has high specificity but fluorescent microscopy is more sensitive and time taken for the examination of the slide with fluorescent microscope is quite less as compared to with Ziehl Neelsen staining. Fluorescent microscope require light with the help of mercury vapour lamp which is costly and require daily regular maintenance. So to cut the cost factor Light-emitting diodes (LED) have been developed. Moreover dark room is required for fluorescent microscope which is not the case with LED microscope. World Health Organization (WHO) in 2009 assessed the efficacy of LED microscope and found it to be at par with the fluorescent microscopy. The operational cost of LED microscope was found to be less than both conventional ZN staining as well as fluorescent microscope. The advantages of fluorescence staining procedure are its simplicity and examination rapidity since it utilizes lower magnification compared to Z-N staining ($\times 40$ vs. $\times 100$). Fluorescent microscope may take up to 75% less time than a conventional microscope. This advantage would be a tremendous benefit for overburdened laboratory system in many low resource settings.^{3,4}

On the basis of these findings, WHO recommended to various governments in endemic countries that they should shift over to LED microscopy, and that LED microscopy should replace conventional Ziehl-Neelsen light microscopy in the long run. Fluorescent microscopes are provided by the government to the state reference laboratories under Revised National

Tuberculosis Control programme(RNTCP). With these points in mind, a study was undertaken to look for the feasibility of using the Light Emitting Diode (LED) as an efficient replacement for conventional Microscopy in our hospital for the diagnosis of Pulmonary Tuberculosis.

Materials and Methods

234 consecutive sputum samples were collected from patients of all age groups suspected with pulmonary tuberculosis including the immunocompromised patients who came to the outpatient department of tertiary care hospital from 1-1-15 to 31-3-15. Each sample was collected in a sterile, clean, wide mouth container and processed in a biosafety cabinet type II taking all necessary precautions.

ZN Staining: A brand new slide was taken and laboratory number was written on the slide using marking pencil. New slide was taken in order to avoid false positivity because of deposition of carbol fuchsin in scratches. Purulent portion of the sputum was taken with a sterile inoculation loop and a smear of 2 cm × 3 cm in size was prepared. The smear was of optimum thickness so that the printed material was readable through it. Smears were prepared near a flame in a biosafety type II cabinet so as to prevent aerosols formation. The slide was allowed to air dry for 15-30 minutes to clear air bubbles. The smear was fixed by passing the slide over a flame 3-5 times. The protein in the sputum gets coagulated and helped in fixation of the smear. Carbol fuchsin (1%) was poured over the smear, and the slide was gently heated till vapors started rising. The carbol fuchsin was kept on the slide for 5 minutes. Dye penetrates through the wall of the bacilli with the help of heat. The slide was gently washed using running water till excess carbol fuchsin stain was washed away. The smear on the slide looked red. It was rinsed properly and decolorized with 20% sulphuric acid, kept for 2-3 minutes each time till the smear was light pink. Slide was rinsed again and counterstained with 0.1% methylene blue for half a minute. After washing with water and drying, the smear was examined under 100x magnification of light microscope.⁵ (Fig. 1)

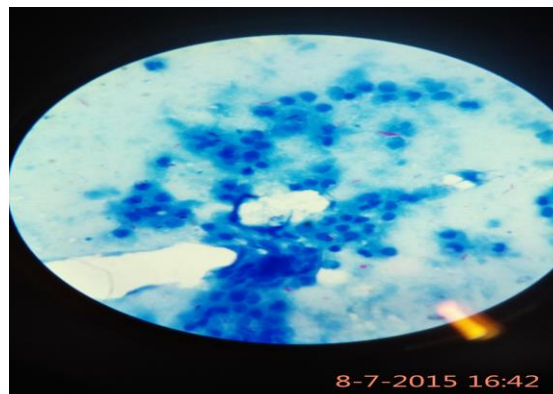


Fig. 1: Ziehl-Nelson stained sputum smear under light microscope.(100X) Bacilli appear as pink coloured rod shape organism

Auramine O staining: Reagents used were Auramine phenol solution, 1% Acid alcohol and .1% potassium permanganate solution.

Preparation of reagents: Auramine phenol solution- Dissolved 3 grams of phenol crystals in 97 ml of distilled water to prepare 3% stock solution. Warmed 100 ml of this stock solution to 40°C and added. 3 grams of Auramine with proper shaking for 10 minutes. Filtered and stored in dark brown bottles.

Preparation of 1% Acid alcohol: Dissolved .5 gram sodium chloride in 25 ml of distilled water and added 25 ml of concentrated hydrochloric acid. To this mixture added 75 ml of alcohol and stored in tight dark coloured glass bottle.

Staining procedure: The slide was placed on the staining rack with the smear facing upwards. Put fresh auramine phenol solution over the smear for 8-10 minutes. Washed with tap water and decolorized by covering with acid alcohol for two minutes. Repeat the decolorization again for two minutes. Again washed with tap water and counterstained with .1% potassium permanganate for half a minute. Washed with water and let the slide air dry. Examined the slide under fluorescent microscope.(Fig. 2) In fluorescent microscopy each field was examined at 250X whereas in ZN staining smear is examined at 1000X. Area examined under fluorescent microscope was larger. Examination of the smear at 250X with fluorescent microscope contained more bacilli than seen with the same smear stained with Ziehl Neelsen staining at 1000X. WHO devised a method for the reporting of the result of AFB observed under fluorescent staining whereby the result should be divided by a magnification correction factor. So, if using objective of 25 the correction factor is 10 i.e. divide the number of organism seen under fluorescent microscope by 10. If objective of 40, the magnification correction factor is 5 i.e. divide the number of organism seen under fluorescent microscope by 5.⁶




Fig. 2: Auramine O stained sputum smear under fluorescent LED microscope.(25X) Bacilli appear as bright yellow organism

Comparative Grading		
ZN staining 100X x 10X	Auramine Fluorescent 25X x 10X	Grading
>10 AFB/ field 20 fields	>100 AFB/field 20 fields	3 Positive
1-10 AFB/ field 50 fields	11-100 AFB/field 50 fields	2 Positive
10-99 AFB/ 100 fields	1-10 AFB /100 fields	1 Positive
1-9 AFB/100 fields	1-3 AFB / 100 fields	Doubtful Positive/ Scanty/ Repeat
No AFB/ 100 fields	No AFB /100 fields	Negative

Patients showing positive result with both the methods or with either of the methods were confirmed with PCR before starting the anti tubercular treatment.

Observation

A Total of 234 pulmonary tuberculosis suspects were included in the study.

Out of 234 sputum samples 62(26.5%) sputum samples were positive for AFB with Ziehl-Nelson and 84(35.9%) sputum samples were positive for with fluorescent microscopy.

Table 1: Showing results of smear examination by ZN staining and LED fluorescent staining

Staining method	Number of positive cases	Number of negative cases
ZN method	62	172
LED fluorescent microscopy	84	150

Table 2: Shows comparison of smear result by ZN staining and LED fluorescent staining

	ZN Positive	ZN Negative	Total
Flouroscent positive	60	24	84
Flouroscent negative	2	148	150
Total	62	172	234

Table 3: Correlation of ZN staining and LED fluorescent staining grade wise

Grading	Positive by flouroscent staining	Positive by ZN staining
scanty	9	3
1+	19	7
2+	22	20
3+	34	32
Total	84	62

Table 4: Shows grading of cases positive by fluorescent staining and negative by ZN staining

Grading	Positive by Flourescent method only
Scanty	8
1+	12
2+	2
3+	2
Total	24

Whereas the two cases showing positivity only by ZN staining method were having the grading as scanty. The remaining smears (148) were negative by both the methods.(Table 2) These 24 cases positive by either fluorescent microscopy or conventional microscopy were further subjected to PCR. All the 24 cases were positive for mycobacterium tuberculosis.

Discussion

Our findings are in concurrence with the previous studies which shows that fluorescence microscopy is better than Ziehl Neelsen microscopy. In an endemic country like India where disease prevalence is more and resources are limited, there is high potential of using LED microscopy to examine a smear. The lower magnification of the fluorescent and LED microscopy (250X) compared with light microscopy(1000X) helps to screen smear faster as well as increases the sensitivity of the results. In patients with less bacterial load Zeihl Neelsen staining can easily miss the diagnosis. But the use of Fluorescent Microscopy increases the diagnostic value of test. The method saves both time and precious expenses and is ideal for laboratories having larger workload.⁷ Fluorescent staining is superior to ZN staining in the presence of a low bacterial load but when the smear shows cytomorphological features of tuberculosis or granuloma

formation then smear positivity by ZN staining is nearly as good as the fluorescent method.^{8,9} Our study also confirms that the LED provides alternate cost effective light source for fluorescence microscopy. LED light source are cheaper than the mercury vapour lamps used in fluorescent microscopy and are easily available. As low energy is required for the LED microscopy so in rural areas with frequent power failures battery operated LED microscopes can be easily used. With LED microscopy we observed that tubercle bacilli could be visualized without a darkroom but some observer's preferred seeing the slide when microscope was in the dark environment. This further requires more evaluation before we come to some conclusion as reported in previous studies. LED microscope would be a great asset in rural areas to reduce the time required to examine large number of smears without delay.⁷⁻⁹

In the present study, out of 234 sputum samples 62(26.5%) and 84(35.9%) sputum samples were positive with Ziehl-Nelson and led fluorescent microscopy respectively. Similar results have also been revealed by studies conducted by different authors in different settings.(Table 5)

Table 5: Showing comparative results with ZN staining and Fluorescent staining in different studies

Author	ZN staining(%) Positive	Fluorescent staining(%) positive
Ben et al ¹⁰	10.9	14.9
Laifangbam et al ¹¹	44.1	71.6
Githui et al ¹²	65	85
Jain et al ¹³	32	41

This shows that LED based fluorescent microscopic staining of sputum is a better method for detecting tubercle bacilli than conventional microscopy with Z-N staining. As our study was done on less number of specimens so it failed to prove statistically significant differences. But it can be safely said that LED microscopy offers an good alternative with better performance to Ziehl Neelsen microscopy. Ideally both the staining procedures should be done on the same smear for comparison basis as no two smears can have the same positivity. Doing both the staining procedures on the same smear (i.e. ZN staining after Auramine-O staining by destining) can affect the result of the staining procedure as seen in previous studies.⁴ However, in our study we used different slides for the both the Ziehl Neelsen staining and LED staining inspite of the fact that different smears made from the sample could be variable. Recently a study in Africa showed conventional ZN smear microscopy is better than LED/FM in patients of HIV-TB coinfections.¹⁴ Conventional microscope with ZN stain detects tubercle bacilli, but it takes lot of time to examine the slides, furthermore it has been demonstrated that low cost

LEDs could be a viable alternative to Mercury Vapor lamps used in fluorescent microscopy. Thus LED based fluorescent microscope with auramine stain takes less time compared with conventional microscope with Z-N stain and even small number of organisms in the smear can be picked up by the LED based fluorescent microscope. Also, the latter can be performed with minimum days of training. In Z-N staining method, we have to search for organisms carefully, but in fluorescence staining the organisms stare at us, because of fluorescence light. Additional advantage is that a colour blind person can also use the method without difficulty.⁷⁻⁹ High cost and dark room required for fluorescent microscope are major factors responsible for less use of fluorescent microscope requirement of special settings for fluorescent microscope becomes some of its major drawbacks. Light Emit Diode Microscope is easy to operate than fluorescent microscope and is less expensive on long term use. So it can be easily maintained in rural laboratories of endemic country like India. In the present study tuberculosis was found to be more common in males(69%) than females(31%). Similar results have been shown by other studies.^{2,15} This may reflect either higher prevalence of tuberculosis in males or simply that more males patients visit the OPD compared to female patients. However studies in large cross section of population are required before coming to any conclusion. In our country government has started providing LED Microscopes to Microscopy Centers in selected Medical Colleges.

Conclusion

Keeping in mind the current explosive situations of tuberculosis in our country and the rest of world, there is an urgent need for control of tuberculosis by early detection and prompt treatment to prevent the transmission of bacilli from the diseased to the healthy. LED based fluorescent microscopy with auramine stain takes lesser time compared to conventional microscopy with ZN stain besides the ability of detecting even small number of tubercle bacilli. These are added advantages for implementing LED microscopy in a country like India, especially in resource limited settings with high burden of tuberculosis. Our study shows that LED microscopy offers an effective alternative with better diagnostic performance than ZN microscopy which may be further confirmed with large cross sectional studies.

Bibliography

1. World Health Organization. Global Tuberculosis report 2014. Geneva, Switzerland: WHO; 2014.
2. Prasanthi K, Kumari AR. Efficacy of fluorochrome stain in the diagnosis of pulmonary tuberculosis co-infected with HIV. *Indian J Med Microbiol* 2005;23(3):179-81.
3. Affolabi D, Torrea G, Odoun M, Senou N, Ali Ligali M, Anagonou S et al, Comparison of two LED fluorescence

- microscopy build-on modules for acid- fast smear microscopy. *Int J Tuberc Lung Dis* 2010;14(2):160–4.
4. Marais BJ, Brittle W, Painczyk K, Hesselning AC, Beyers N, Wasserman E et al. Use of light-emitting diode fluorescence microscopy to detect acid-fast bacilli in sputum. *Clin. Infect. Dis* 2008;47(2):203-7.
 5. Revised National Tuberculosis Control Program (RNTCP), Module for Laboratory Technicians, Central TB Division, Directorate General of Health Services, Ministry of Health and Family welfare, New Delhi March: 2006.
 6. WHO. Fluorescent Light Emitting Diode (LED) Microscopy for diagnosis of tuberculosis. Policy statement; Geneva/Sweden: 2011.
 7. Suria Kumar J, Chandrasekar C, Rajasekaran S. Comparison of conventional and fluorescent staining methods in diagnosis of pulmonary tuberculosis among HIV seropositive individuals. *J Evol Med Dent Sci* 2012;1(4):463-6.
 8. Bhumbra U, Gyaneshwari. A comparative study of ziehl-nelson staining and auramine staining in sputum sample for the diagnosis of Pulmonary tuberculosis. *Int J Biomed Res* 2014;5(6):383-5.
 9. Goyal R, Kumar A. A Comparison of Ziehl-Neelsen Staining and Fluorescent Microscopy for Diagnosis of Pulmonary Tuberculosis. *J of Dental and Medical Sci*. 2013;8(5):05-08.
 10. Ben J. Marias, Wendy Brittle, Katrien Painczyk, Anneke C. Hesselning, Nulda Beyers, Elizabeth Wasserman, Dick van Sooling and Rob M Warren; Use of Light – emitting diode fluorescence microscopy to detect acid fast bacilli in sputum. *Clinical infectious diseases* 2008;47:203-7.
 11. Laifangbam S, Singh HL, Singh NB, Devi KM, Singh NT. A comparative study of fluorescent microscopy with Ziehl Neelsen staining and culture for the diagnosis of pulmonary tuberculosis; Kathmandu Univ Med J (KUMJ), 2009;7 (27):226-30.
 12. Githui W, Kitui F, Juma ES, Obwana DO, Mwai J, Kwamanga D. A comparative study on the reliability of fluorescent microscopy & Ziehl-Neelson method in the diagnosis of pulmonary tuberculosis. *East Afr Med J*. 1993;70(5):263-6.
 13. Jain A, Bhargawa A, Aggarwal SK. A comparative study of two commonly used staining technique for acid fast bacilli in clinical specimens. *Ind J Tub* 2002;49:161-2.
 14. Cattamanchi A, Davis JL, Worodria W, Den Boon S, Yoo S, Matovu J, et al, Sensitivity and specificity of fluorescence microscopy for diagnosing pulmonary tuberculosis in a high HIV prevalence setting. *Int J Tuberc Lung Dis*,2009;13(9):1130–6.
 15. Rajasekaran S, Uma A, Kamakshi S, Jayaganesh D, Senlhanizhelelvan A, Savitry S et al. Trends of HIV infection in patients with tuberculosis in rural south India. *Ind J Tub* 2000;47:223-6.

How to cite this article: Khanna A, Sharma P, Sharma S, Khanna M. Comparison of conventional Ziehl Neelsen staining with LED Fluorescent staining for pulmonary tuberculosis cases. *Indian J Microbiol Res* 2016;3(4):363-367.