

A rare case of Diphyllbothriasis and Megaloblastic anaemia in a middle-aged lady from South India

Ashrafulla MR¹, Md. Mudassar Iqbal Lodhi^{2,*}, Giridhar R. Kuknoor³, Shashidhar Katakol⁴

¹Pathologist, Dept. of Pathology, District Hospital, Dharwad, Karnataka, ²Assistant Professor, Dept. of Microbiology, Icare Institute of Medical Sciences and Research, Haldia, West Bengal, ³District Surgeon, ⁴Senior Consultant Physician, Dept. of Medicine, District Hospital, Dharwad, Karnataka

***Corresponding Author:**

Email: mudassar_lodi2003@yahoo.co.in

Abstract

Tapeworms (Cestoda) continue to be an important cause of morbidity in humans worldwide. Diphyllbothriasis, a human disease caused by tapeworms of the genus *Diphyllbothrium*, is the most important fish-borne zoonosis caused by a cestode parasite. We report a rare case of *Diphyllbothrium latum* from South India seen in a middle-aged lady with two month history of vague abdominal pain, spontaneous passage of proglottids in stool, on and off diarrhea and megaloblastic anaemia. Treatment with niclosamide ultimately led to resolution of her symptoms.

Keywords: *Diphyllbothrium latum*, Megaloblastic anaemia, South India

Introduction

Diphyllbothrium latum, commonly known as fish tapeworm, belonging to the pseudophyllidean tapeworm group, is worldwide in distribution, but most prevalent in cool lake regions where raw or pickled fish is popular, such as Northern, Central and Eastern Europe (including Russia), Japan, Chile, Argentina and the Great lakes areas of USA and Canada.⁽¹⁾ We report a rare case of diphyllbothriasis (infection with *Diphyllbothrium latum*) from Dharwad, South India, in a middle aged lady.

Case Report

A 40 years old lady presented to the Medicine OPD of the District Hospital Dharwad, Karnataka in April 2017 with history of pain abdomen and passage of cream coloured tape-like structures in stool since two months. She also gave on and off history of diarrhea and easily fatigability. She was a non-vegetarian and an occasional fish eater. During the diarrheic episodes, her stools were semisolid in consistency and contained no blood or mucus. No similar complaints were present in her family.

General physical examination was insignificant except for mild pallor.

Routine examination of stool sample showed undigested food particles and cream coloured tape-like structures, indicating some tapeworm infestation. Wet mount preparation showed the presence of large number of oval shaped, bile stained eggs, measuring approximately 70 μm \times 45 μm with an operculum at one end. [Fig. 1]. Typical proglottids, broader than the length, were identified. However there was no identifiable scolex. [Fig. 2]. On the basis of the morphology of the eggs with operculum and the presence of broader than long segments, the parasite was identified as *Diphyllbothrium latum*. Blood picture revealed hemoglobin of 9.7 g/dL and a total count of 8500/mm³. Differential counts were within normal limit except for eosinophil slightly raised (9%). The peripheral blood smear showed hypersegmented neutrophils suggesting megaloblastic anaemia. [Fig. 3]. She was treated with a single dose of Niclosamide 2g and follow-up stool test for ova and parasites done two weeks later were negative. Her hemoglobin level was also increased to 12 g/dL done three months later.

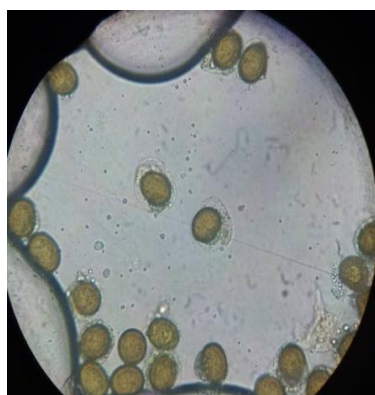

Fig. 1: Eggs of *D. latum*



Fig. 2: Proglottids of *D. latum*

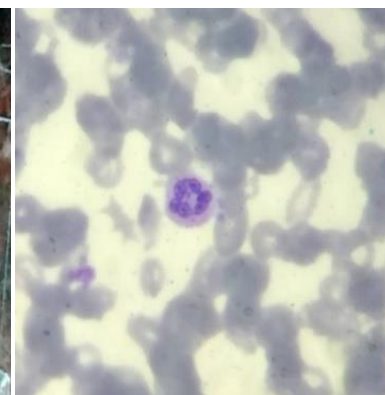


Fig. 3: Hypersegmented neutrophils

Discussion

Most *D. latum* infections are asymptomatic, although manifestations may include transient abdominal discomfort, diarrhea, vomiting, weakness, and weight loss. Occasionally, infection can cause acute abdominal pain and intestinal obstruction. In rare cases, cholangitis or cholecystitis may be produced by migrating proglottids. Because the tapeworm absorbs large quantities of vitamin B₁₂ and interferes with ileal B₁₂ absorption, vitamin B₁₂ deficiency can develop, but this effect has been noted only in Scandinavia, where up to 2% of infected patients, especially the elderly, have megaloblastic anemia resembling pernicious anemia and may exhibit neurologic sequelae of B₁₂ deficiency.⁽²⁾ Our patient had abdominal symptoms, easy fatigability as well as peripheral blood smear showing hypersegmented neutrophils suggestive of megaloblastic anaemia due to vitamin B₁₂ deficiency. Hypersegmentation was more sensitive than mean cell volume (MCV) or red cell distribution width (RDW) in detecting B₁₂ deficiency. The MCV and the RDW should not be relied on when screening for B₁₂ deficiency, examination of the blood smear for hypersegmentation is essential.⁽³⁾

Although widespread in distribution, diphyllobothriasis is often not reported in India.⁽⁴⁾ Scanty reports of diphyllobothriasis are available in literature from Southern India which may be attributed to the fish-eating habit of the people in this part of the country. It is speculated that these infections may be misdiagnosed as taeniasis.⁽⁵⁾

The diagnosis is made readily by the detection of the characteristic eggs in stool and also the treatment available is very simple. Doctors should be made aware of the possibility of this infection.⁽⁶⁾

The previous literature revealed that cases reported in India were in paediatric patients, however ours is a middle aged lady similar to what has been observed in recent Korean cases of diphyllobothriasis, which involved middle-aged individuals.⁽⁷⁾

Our findings suggest the probable undiagnosed or underreported parasite in patients. Although a rare cause of vitamin B₁₂ deficiency, diphyllobothriasis should be considered in the differential for unexplained cases of macrocytosis, as it is a treatable cause of vitamin B₁₂ deficiency.⁽⁸⁾ Treatment of human cases does not seem to represent a serious problem at present, unlike a generally low awareness of the infection risk when eating raw or undercooked fish. Better education of all population segments, such as consumers, health professionals, fishermen and sellers, particularly in the regions under potential risk of infection, is necessary.⁽⁹⁾

Conclusion

We therefore emphasize the need to suspect fish tapeworm infection and recommend epidemiological study of *Diphyllobothrium* spp. infection, as the

infections, if undiagnosed or underreported, can lead to considerable morbidity.

References

1. Chakraborty P. Textbook of Medical parasitology; second edition: 217-223.
2. Longo, Fauci, Kasper, Hauser, Jameson and Loscalzo. Cestode infections. Harrison's principles of internal medicine. 18th edition.
3. Thompson WG, Cassino C, Babitz L et al. Hyper segmented neutrophils and vitamin B₁₂ deficiency. Acta Haematol. 1989; 81: 186-191.
4. Ramana KV, Rao S, Vinaykumar M, Krishnappa M, Reddy R, Sarfaraz M, Kondle V, Ratnamani MS and Rao R. Diphyllobothriasis in a nine-year-old child in India: a case report. Journal of Medical Case Reports. 2011; 5(1): 332.
5. Devi CS, Shashikala, Srinivasan S, Murmu UC, Barman P, Kanungo R. A rare case of diphyllobothriasis from Pondicherry, South India. Indian J Med Microbiol. 2007; 25: 152-154.
6. Chou HF, Yen CM, Liang WC and Jong YJ. Diphyllobothriasis latum: the first child case report in Taiwan. Kaohsiung J Med Sci. 2006 22(7): 346-351.
7. Lee EB, Song JH, Park NS, Kang BK, Lee HS, Han YJ, Kim HJ, Shin EH, Chai JY. A case of *Diphyllobothrium latum* infection with a brief review of diphyllobothriasis in the Republic of Korea. Korean J Parasitol. 2007; 45(3): 219-223.
8. Mocanu V and Rebello R. A Fishy Tale of Macrocytosis. DMJ. Spring 2015; 41(2): 16-19.
9. Scholz T, Garcia HH, Kuchta R and Wicht B. Update on the Human Broad Tapeworm (Genus *Diphyllobothrium*), Including Clinical Relevance. Clin. Microbiol. Rev. 2009; 22(1): 146-160.

How to cite this article: Ashrafulla MR, Lodhi MI, Kuknoor GR, Katakol S. A rare case of *Diphyllobothriasis* and *Megaloblastic anaemia* in a middle-aged lady from South India. Indian J Microbiol Res 2017;4(4):471-472.