

## COMPOUND COMPOSITE ODONTOMA: TWO CASE REPORTS AND ITS REVIEW

Narendra Trymbak Chaudhari<sup>1\*</sup>, Navneet Kamalprasad Sharma<sup>2</sup>,  
Divya Ramakant Kanodia<sup>3</sup>, Saroj Kumar Sethy<sup>4</sup>

<sup>1</sup>Assistant Professor, Dept. of Oral Pathology & Microbiology,

<sup>2</sup>Assistant Professor, <sup>4</sup>Dental Surgeon, Dept. of Oral & Maxillofacial Surgery,

<sup>3</sup>Intern, Government Dental College and Hospital (GDC & H), Mumbai.

**\*Corresponding Author:**

E-mail: naren.njoi@gmail.com

---

### ABSTRACT

*Odontoma is classified as neoplasm but its clinical presentation resembles hamartomatous growth. They are the most common type of odontogenic tumors with limited growth potential and low recurrence rate. Compound and complex odontomas are the most commonly recognized types which are seldomly associated with complications. Early diagnosis and prompt treatment is key to successful management. In order to make dental professionals aware of this odontogenic tumor that frequently affects young age group; two cases of compound composite odontoma are reported along with a brief discussion on odontomas.*

**Keywords:** *Odontoma, Hamartomatous, Composite, Compound, Complex.*

---

### INTRODUCTION

The term odontomas derived from Greek ‘odous’- tooth + ‘oma’- tumor which means a dental tumor, but it’s a misnomer as all the tumors derived from dental formative tissues are not termed odontomas.<sup>1</sup> Odontoma is defined as “a tumor that has developed and differentiated enough to produce enamel and dentin.”<sup>2</sup>

Odontomas are conceived as hamartomatous malformation rather than true neoplasm as they formed due to malformation and abnormal proliferation of both epithelial and mesenchymal components of dental tissues. They neither show continuous growth nor infiltrate into surrounding tissues. They may originate from an extraneous bud of odontogenic cells of the dental lamina and are frequently associated with impacted teeth and retained deciduous teeth.<sup>3</sup>

Odontomas are classified histologically as **Compound odontomas** that show multiple tooth-like structures and radio graphically appear as opacities and **Complex odontomas** which comprise of a mixture of odontogenic tissues without dental organization. Clinically odontomas may present as central (intraosseous) odontoma, peripheral (extraosseous or soft tissue) odontoma and erupted odontoma.<sup>4</sup>

To prevent imminent complications associated with eruption of the primary and permanent teeth, timely diagnosis and management of odontomas is essential<sup>4</sup> as it would result in less complex treatment and preservation of the impacted teeth by various treatment modalities and to ensure that regular radiological examination in the first two decades of life can be employed.<sup>5</sup> We present here two cases of compound composite odontoma and a brief account on odontomas.

### CASE REPORT

**Case 1:** A 26 year old male patient visited our hospital with a complaint of missing tooth in 11 regions. The family and medical history were unremarkable. Patient gave past history of extraction of over retained 51 around fifteen days back. Oral examination revealed missing 11. Nodular swelling which was hard in consistency along with slight expansion of alveolus was seen in the 11 region (Fig 1). Radiographic examination showed impacted 11. Multiple radiopaque calcified structures with radio density equal to that of tooth structure were seen in the region of upper right central incisor. Unerupted 11 were seen as its eruption is hindered by the calcified mass which was surrounded by thin radiolucent line (Fig 2).

**Case 2:** A 12 year old female patient came to our OPD with chief complaint of missing teeth in upper anterior region. The family and medical history were not relevant. The past dental history revealed missing 11, 22 since many years. No H/O of trauma or extraction.

Oral examination showed a hard bulge on edentulous ridge in the region of missing 11 (Fig 6). Also 22 were missing. Orthopantomograph showed radiopaque mass in 11 regions. Cone-Beam Computed Tomography demonstrated a calcified mass fused to the impacted 11. Also a small calcified structure about 0.5 cm was seen in midline near the floor of the nose (Fig 9).

Provisional diagnosis of a multiple compound odontoma was made in both cases and the patients were advised surgical removal of the lesion. Under local anesthesia of 2% lidocaine with 1:80,000 epinephrine, a mucoperiosteal flap was raised (Fig 7). The mass was luxated using forceps, and tooth-like

structures were extracted. The central incisor was also extracted in both cases as it was placed unfavorably in case 1 and fused to odontome in case 2. The extracted sockets appeared normal, and the area was curetted thoroughly (Fig 3), and closed with 3.0 black breaded silk suture. The extracted tooth and masses were sent for pathological examination. Healing of the area was uneventful, and one week after the surgery, the sutures were removed. Patient was advised prosthodontic treatment for correction of the space.

The specimen were decalcified using 10% HNO<sub>3</sub>, fixed in formalin and paraffin embedded wax blocks were prepared. 4µm sections were made using a microtome and then subjected to tissue stains.

**Pathology report: Case 1:** Macroscopic examination showed four tooth-like structures which were grossly deformed and disorganized except one which resembled the unerupted right maxillary central incisor (Fig 4). **Haematoxylin & Eosin stained** section showed tooth like and haphazard arrangement of dental hard and soft tissue including cementum, dentin and pulp consistent with a compound odontome (Fig 5).

**Pathology report: Case 2:** On macroscopic examination one large and another small calcified tooth like structures were seen. The larger mass showed fused crowns and two divergent and curved roots representing union between an unerupted incisor and odontome (Fig 8). **Haematoxylin & Eosin stained** section showed multiple tooth like structures consisting of dentin with enclosed pulp along with pulp stones, enamel matrix and cementum like areas surrounded by dense connective tissue capsule (Fig 10, 11, 13). Ghost cells and calcifications were seen in connective tissue (Fig 12); overall features suggestive of compound odontoma. A special stain like Masson's trichrome stain was used to demonstrate pulp collagen, pulp stones and dentin (Fig 14, 15) and Van Gieson was used to demonstrate the collagen of capsule (Fig 16). Based on above features a diagnosis of compound composite odontoma was made in both cases.

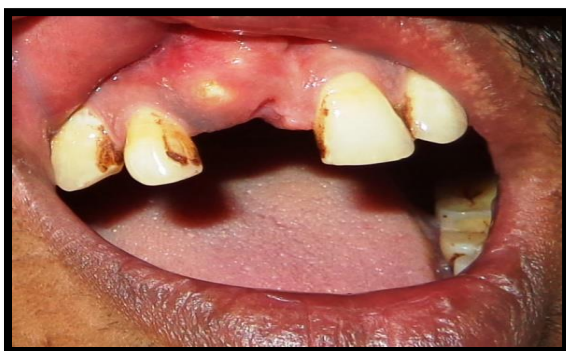

Fig. 1: Clinically nodular swelling seen (case 1).

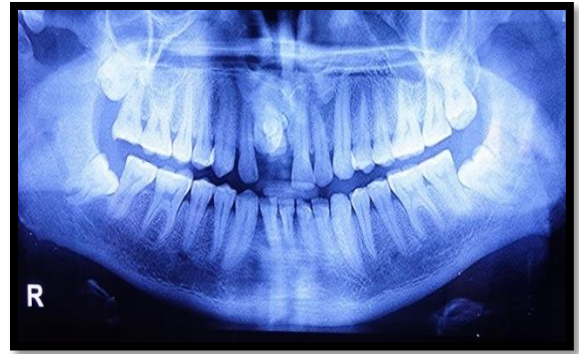

Fig. 2: OPG shows multiple radiopacities (case 1).

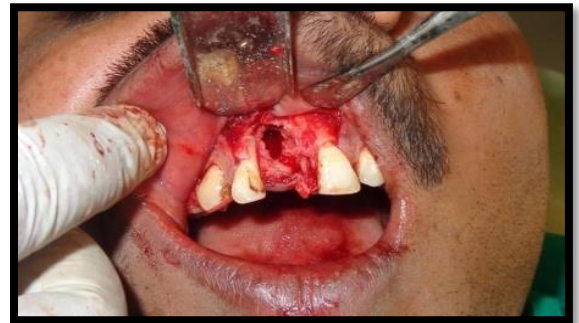

Fig. 3: Post-surgical view (case 1).

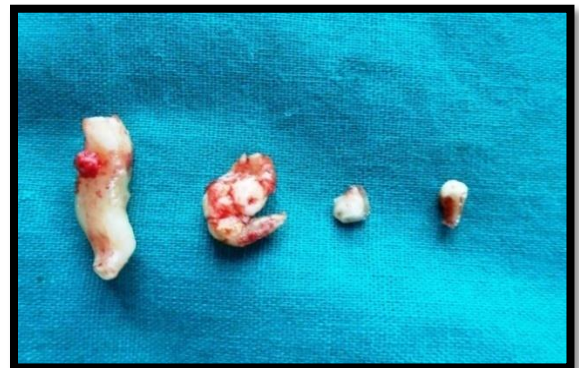

Fig. 4: Grossly deformed four tooth-like structures (case 1).

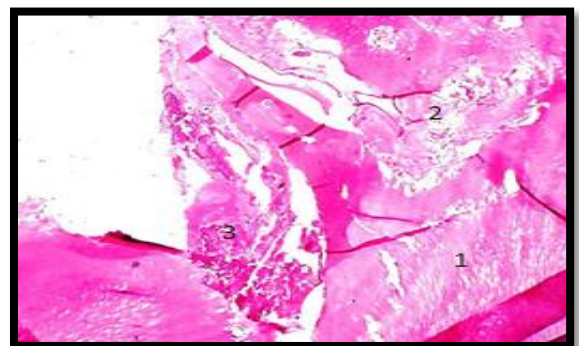


Fig. 5: H&E 100X shows 1.dentin, 2.pulp and 3.cementum (case 1).

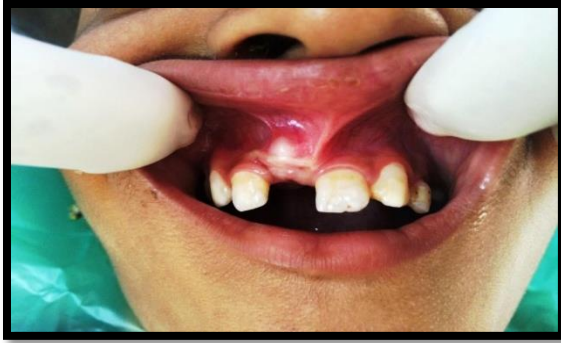

Fig. 6: Clinically bulging seen which is hard in consistency (case 2).

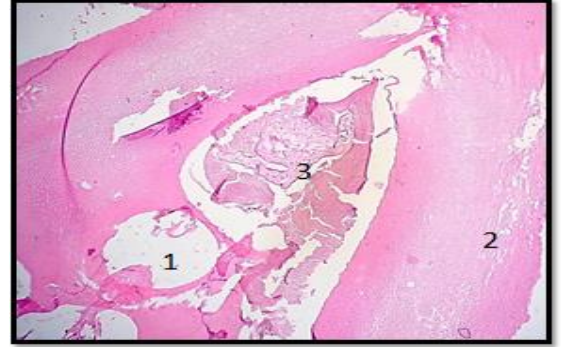


Fig. 10: H&E under 100X: 1.enamel spaces, 2.dentin, 3.pulp (case 2).

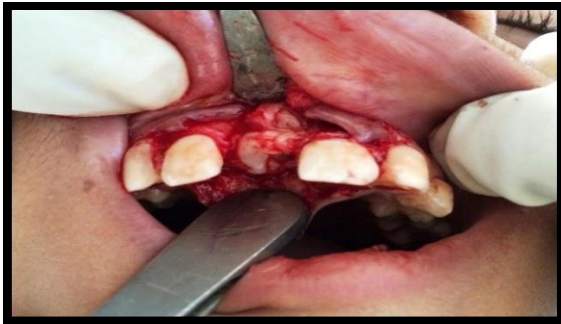

Fig. 7: Mucoperiosteal flap reflection during surgery (case 2).

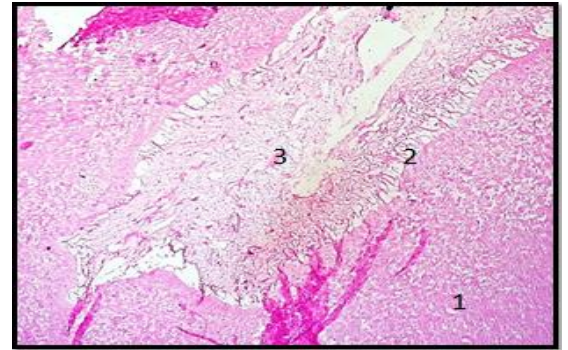


Fig. 11: H&E under 100X: 1.dentin, 2.odontoblast, 3.pulp (case 2).

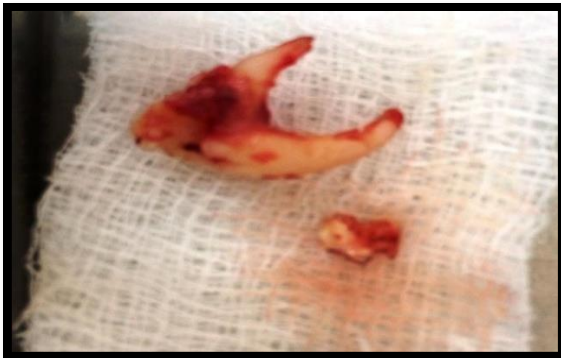

Fig. 8: Macroscopic appearance of odontoma (case 2).

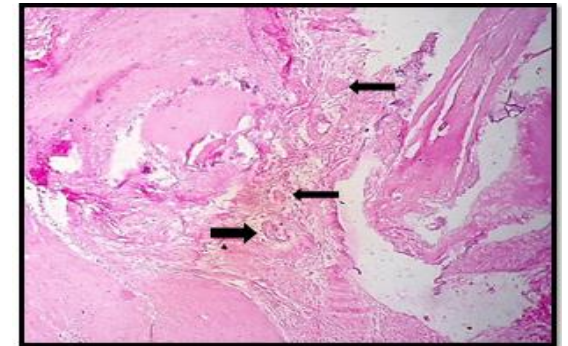


Fig. 12: H&E under 100X shows connective tissue capsule containing ghost cells (arrow). (case 2)

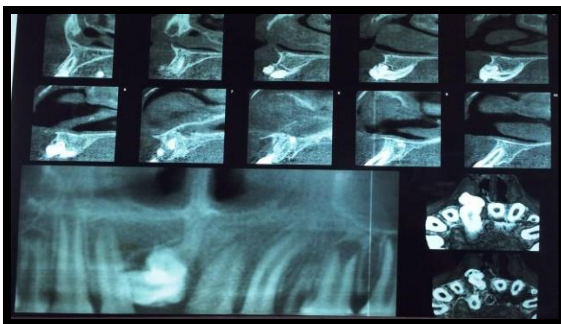


Fig. 9: CBCT& OPG shows radiopaque mass fused to 11(case 2).

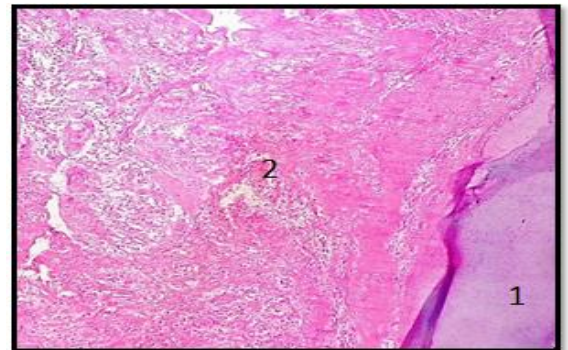
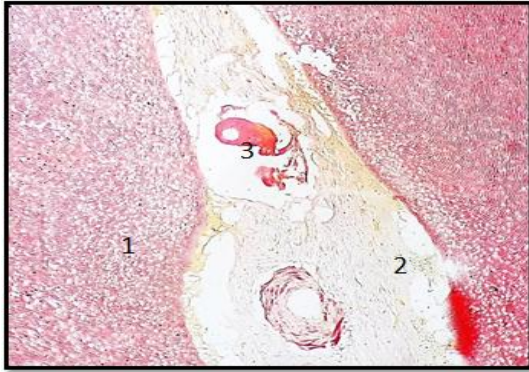
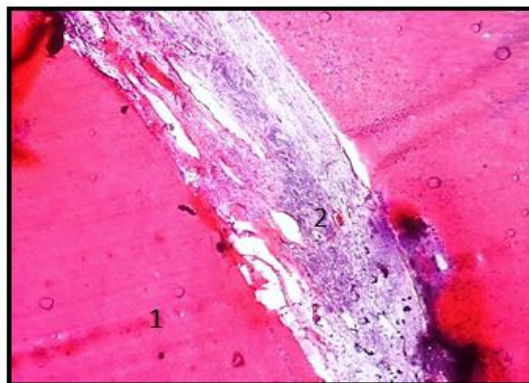


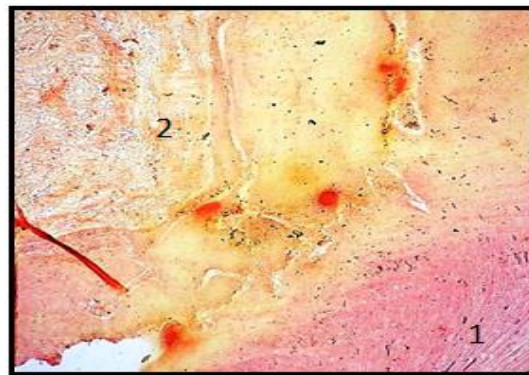
Fig. 13: H&E under 100X: 1.enamel matrix 2.capsule (case 2).



**Fig. 14: Masson's trichrome stain under 100X: 1.dentin, 2.pulp, 3.pulp stones (case 2).**



**Fig. 15: Masson's trichrome stain under 100X: 1.dentin, 2.pulp collagen (case 2).**



**Fig. 16: Van gieson stain under 100X: 1.dentin, 2.collagen (case 2).**

## DISCUSSION

Odontomas are the most frequently seen benign odontogenic neoplasms which demonstrate normal structures without proper organization owing to disordered expression and localisation of the extracellular matrix molecules in the dental mesenchyme.<sup>6</sup> The term 'Odontoma' was coined by Paul Broca in 1867.<sup>7</sup> Odontomas encompass about 22% of all odontogenic tumors with incidence of 5.3%-11.6% in India.<sup>8</sup>

Ameloblastic Fibroma (AF), Ameloblastic Fibrodentinoma (AFD), Ameloblastic Fibroodontoma (AFO) and Odontomas are classified as benign mixed odontogenic tumors. A continuum concept was suggested which states that AF will mature and finally result in odontoma but this theory is not widely accepted, as recurrent AF do not show dental hard tissue formation and AF occurs after completion of odontogenesis i.e. after 20 years. It was also proposed that locally hyperactive dental lamina may result in "multiple schizodontia" leading to formation of compound odontomas.<sup>9</sup>

Odontomas comprise of enamel which arises from odontogenic epithelium and dentin which develops from odontogenic mesenchyme, hence also referred as "Composite Odontomas" as they are composed of both cell types.<sup>10</sup>

**Age/Sex/Site:** Odontomas are usually detected in the second decade of life with no specific gender predilection.<sup>5</sup> There is specific site predilection for odontomas with compound variety located in anterior maxilla whereas complex type in posterior mandible region in ratio of about 2:1 with respect to the incidence<sup>11</sup> with right side of the jaw more frequently involved.<sup>10</sup> Mostly such cases are diagnosed in the second and third decades of life by its usual radiographic appearance.<sup>11</sup>

**Etiology:** The etiology of the odontoma is unknown, but different factors implicated may be history of trauma during primary dentition, inflammatory/infectious processes, hereditary anomalies (Gardner's syndrome, Hermann's syndrome), odontoblastic hyperactivity or alterations of the genetic components involved in monitoring tooth development,<sup>11</sup> developmental anomaly like persistent dental lamina<sup>7</sup> which may lead to growing of extra odontogenic epithelial cells resulting in odontoma formation.<sup>12</sup>

**Radiology:** Usually odontomas appear as dense radiopacities surrounded by a thin radiolucent halo suggestive of connective tissue capsule. Depending upon the degree of calcification of the lesion three developmental stages is seen. The first stage is radiolucent due to the absence of dental tissue calcification. The second or intermediate stage presents partial calcification, and the third stage is radiopaque with significant calcification. Compound odontomas show multiple radio-opacities with variations in form and size, consistent to denticles. In complex odontoma non-specific, disorganized, irregular radio-opacity in form of a single or multiple structures is seen.<sup>11</sup>

**Histopathology:** Histologically odontoma is not a diagnostic impasse as it consists of dental hard and soft tissues like dentin, cementum,<sup>10</sup> pulp tissues with odontoblastic cells<sup>11</sup> and enamel matrix. The mature enamel is predominantly made of inorganic tissues hence it is lost during the process of

decalcification and instead will be seen as empty spaces. The compound odontoma shows almost a complete organization resembling normal tooth structures, while complex odontoma shows haphazard arrangement of odontogenic tissues.<sup>13</sup> which results in unrecognizable clinical picture of odontomas.<sup>4</sup> The calcified mass is usually surrounded by fibrous connective tissue capsule which resembles follicle of a normal tooth<sup>7</sup> and dentigerous cystic lining<sup>13</sup> along with few degenerative odontogenic epithelial islands has also been reported in some cases.<sup>1</sup> Ghost cells i.e. swollen epithelial cells<sup>11</sup> may be seen along with spherical dystrophic calcification, enamel concretions and sheets of dysplastic dentin.<sup>14</sup>

**Complications:** The common teeth problems encountered because of odontomas are impaction, in which maxillary central incisor being most common; tooth displacement, malformation, reabsorption and devitalization of the adjacent teeth.<sup>15</sup> Delayed eruption of the primary and permanent teeth or over retained primary teeth is another common finding.<sup>11</sup> Odontomas are rarely associated with pain, suppuration, and expansion of bone due to secondary infection.<sup>15</sup>

Various cystic lesions like dentigerous cysts, odontogenic keratocysts, and calcifying odontogenic cysts have also been reported with odontomas.<sup>15</sup> Also ameloblastomatous component developing in odontoma leads to a rare odontogenic tumor termed "odontoameloblastoma".<sup>16</sup>

In most cases development of odontoma is a result of trauma to the primary predecessors, hence the crown of the permanent tooth germ is displaced and remaining tooth structure forms at an angle which results in dilacerations.<sup>15</sup>

**Treatment:** There is no universal consensus on therapeutic approach for impacted teeth associated with odontomas and decision depends upon the position of impacted tooth.<sup>17</sup> Surgical excision of the lesion with or without impacted teeth,<sup>5</sup> maintenance of the arch space till the impacted teeth erupts if in favorable position or prosthetic appliance are the most common ways of treating odontomas.<sup>17</sup> To guide the impacted tooth into its position an orthodontic device can be used.<sup>7</sup>

**Management and Recurrence:** The surgical management should include proper curettage of soft tissue enveloping the odontomas to prevent any chances of cystic degeneration or recurrence due to persistent lining epithelium.<sup>6</sup> Also odontomas show less incidence of recurrence as they are well capsulated lesions.<sup>18</sup>

The radiographic picture of ameloblastic fibro-odontomas and odontoameloblastomas is confusing with odontomas hence it is of paramount

importance to send all the specimens to an oral pathologist for microscopic examination.<sup>7</sup> To ensure proper patient care routine clinical as well as radiographic follow-up should be advised.<sup>5</sup>

## CONCLUSION

Odontomas are benign tumors commonly seen in oral cavity with little clinical signs and come across frequently as accidental findings on radiographs. Odontomas usually cause delayed teeth eruption or impacted teeth and its early diagnosis leads to less complex and less expensive treatment and ensures better prognosis.

Dentists should be aware and have adequate understanding of these lesions for early diagnosis and management to avoid teeth complications also such lesions can be completely treated with less chance of recurrence. We discussed here two cases of compound composite odontomas along with a brief review on odontomas.

## REFERENCES

1. RV Subramanyam: Misnomers in Oral pathology, Oral diseases, November 2010,16;8:740-746.
2. Santosh Patil, Farzan Rahman Shoab, R Tipu: Odontomas: Review Of Literature and Report of a Case, Oral & Maxillofacial Pathology Journal, 2012,3;1:224-27.
3. Aakarsh V. Jhamb, RameshwarDolas, Prashant Pandilwar: Odontoma: Case series & report of cases complicated by infection and multiple denticles, Open Journal of Stomatology2012,2:44-49.
4. Pedro Paulo de Andrade Santos, Keila Martha Amorim Barroso, Lelia Batista de Souza: Odontomas: Clinicopathologic study of 104 cases and a case report of compound odontoma associated in an unerupted maxillary central incisor in a child, International Dentistry – African Edition,2:5:32-39.
5. Seo-Young An, Chang-Hyeon An, Karp-Shik Choi: Odontoma: a retrospective study of 73 cases, Imaging Science in Dentistry, 2012;42:77-81.
6. P. Amaluk, D. Grubor: Erupted compound odontoma: case report of a 15-year-old Sudanese boy with a history of traditional dental mutilation, British Dental Journal,2008,204;1:11-14.
7. Usha Mohan Das, Deepak Viswanath, Umme Azher: A Compound Composite Odontoma Associated with Unerupted Permanent Incisor: A Case Report, International Journal of Clinical Pediatric Dentistry, 2009;2:2:50-55.
8. Namrata C Gill, Renu Yadav: A rare case of complex odontoma associated with the root of an erupted mandibular primary incisor, Indian Journal of Oral Sciences, 2014,5;2:95-100.
9. Reichart PA, Philipsen HP: Odontogenic Tumors and Allied Lesions. Quintessence, 2004. pp 117-118.
10. John B John, Reena R John, Punithavathy: Compound Odontoma Associated with Maxillary Primary Tooth – A Case Report, Journal of Indian Academy of Dental Specialists, 2010,1;1:49-51.
11. Chong Heon Lee, Gyeong Ju Park: Complex and compound odontomas are clinico-pathological entities, Basic and Applied Pathology, 2008;1:30-33.

12. Mahima V Guledgud, Saikrishna Degala, Karthikeya Patil: Multiple Extensive Complex Odontomas of the Jaws, *International Journal of Dental Sciences and Research*, 2014,2;6:128-132.
13. Brenda L. Nelson, Lester D. R. Thompson: Compound Odontoma, *Head and Neck Pathol* DOI 10.1007/s12105-010-0186-2.
14. Santosh Patil, D.N.S.V Ramesh, A. R Kalla: Complex odontoma: report of two unusual cases, *Braz J Oral Sci*, 2012.11;4:509-512.
15. Sanjay Byakodi, Raghavendra Byakodi, Aparna Aparadh: Atypical odontoma: Report of two cases, *Journal of Cranio-Maxillary Diseases*, 2013,2;2:182-6.
16. Branca Heloisa de Oliveira, Vera Campos, Sonia Marçal: Compound odontoma – diagnosis and treatment: three case reports, *Pediatric Dentistry*, 2001,23;2:151-7.
17. Estela Maris Losso, Eduardo Pizzatto: Complex odontoma associated to a primary maxillary canine: case report, *Revista Sul-Brasileira de Odontologia*, 2009,6;2:204-07.
18. Santosh Patil, Farzan Rahman: Erupted odontomas: a report of two unusual cases, *Revista Sul-Brasileira de Odontologia*, 2012,9;2:199-203.