



Case Report

Association between vaginal microbiota dysbiosis with asymptomatic UTI in pregnant woman and adverse pregnancy outcome- A case report

S. R. Swarna^{1,*}, R Vidyameena², T Bharathi², D Jeyakumari¹

¹Dept. of Microbiology, Jawaharlal Institute of Postgraduate Medical Education and Research, Karaikal, Puducherry, India

²Government General Hospital, Karaikal, Puducherry, India



ARTICLE INFO

Article history:

Received 30-11-2022

Accepted 10-12-2022

Available online 23-01-2023

Keywords:

Vaginal microbiota

Dysbiosis

Lactobacillus spp

Urinary tract infection

Spontaneous abortion

Bacterial vaginosis

Urotypes

Amies test

Nugent score

ABSTRACT

The vaginal microbiota dysbiosis [Bacterial vaginosis (BV)] is a condition in which the predominant *Lactobacillus* spp is replaced by anaerobic bacteria like *Gardnerella vaginalis* and *Mycoplasma hominis* in the women of reproductive age group due to several factors. The women with BV are at a greater risk of acquiring urinary tract infection (UTI). The association of bacterial vaginosis and asymptomatic UTI in pregnant women pose risk for both mother and foetus. Here, a case of adverse pregnancy outcome in pregnant woman with BV and asymptomatic UTI is reported.

This is an Open Access (OA) journal, and articles are distributed under the terms of the [Creative Commons Attribution-NonCommercial-ShareAlike 4.0 License](https://creativecommons.org/licenses/by-nc-sa/4.0/), which allows others to remix, tweak, and build upon the work non-commercially, as long as appropriate credit is given and the new creations are licensed under the identical terms.

For reprint contact: reprint@ipinnovative.com

1. Introduction

Vaginal microbiota comprises of 95% of *Lactobacillus* species and 5% of other microorganisms, such as *Gardnerella vaginalis*, *Staphylococcus epidermidis*, *Mycoplasma hominis*, Streptococcal species, Bacterioides species, *Prevotella bivia*, Peptostreptococci species.¹ The *Lactobacillus* spp is the predominant vagina microbiota in the given microecology and contributes for relatively balanced state of healthy environment of vagina. In addition, the *Lactobacillus* spp exhibits a symbiotic role by lowering the vaginal pH with production of lactic acid and helps to prevent the colonization/ growth of opportunistic and uropathogenic bacteria.

Recent studies from microbial urine culturing, bacterial genome sequencing and metagenomics showed that the female urinary microbiota and vaginal microbiota are

interconnected.² The anatomical proximity between the vagina and the urinary tract suggests that vagina might be the main source of the urinary microbial community. The predominant urotypes of urinary bacterial communities include *Lactobacillus crispatus*, *Gardnerella vaginalis* and *Atopobium vaginae*. Urinary microbiota uses specific adaptations like type I fimbriae to bind to specific urothelial proteins, uroplakins with suitable pH, oxygen tension or nutrient availability and glycosaminoglycan degrading enzymes by *Lactobacillus* or *Streptococcus* to colonise the urinary tract. Therefore, the *Lactobacillus* play an important role in genitourinary health of woman. Imbalance to vaginal microbiota can occur due to various factors such as hormonal levels, sexual habits, hygiene, pregnancy, pharmaceutical treatments, and urogenital infections.³ Such imbalance or dysbiosis results in gynaecologic conditions such as Bacterial vaginosis. This condition is associated with decrease in number of *Lactobacillus* spp in genitourinary tract and favours the frequency of other

* Corresponding author.

E-mail address: srswa_20@yahoo.co.in (S. R. Swarna).

urotypes such as *Prevotella*, *Sneathia*, *Shigella*, *Escherichia*, *Enterococcus*, *Streptococcus* and *Citrobacter*, that could increase the risk for urinary tract infection in females.⁴

In pregnancy, such dysbiosis of vaginal microbiota are associated with increased risk of post abortal infection, early and late miscarriage, postpartum endometritis, preterm premature rupture of membrane and preterm birth. It was reported that the incidence of bacterial vaginosis among pregnant women with asymptomatic urinary tract infection was 34% to 41.8% with adverse pregnancy outcomes like abortion, preterm rupture of membrane etc.^{5,6} Here we discuss a case of vaginal microbiota dysbiosis with asymptomatic urinary tract infection resulted in adverse pregnancy outcome.

2. Case Report

A 28-year-old female in her II trimester was brought to the casualty with mild bleeding and pain abdomen with intermittent cramps. On Physical Examination, she was afebrile with a pulse rate of 82/min and BP-110/80mmHg. Pelvic exam revealed vaginal bleeding with closed cervical os suggestive of threatened abortion. Ultrasound examination of abdomen showed adequate liquor, fundal placenta with foetus weighing 300gm, and good foetal heart sound on day I. History revealed that she got married 9 months ago, with first miscarriage happened earlier during I trimester. No further details about the first miscarriage were known. The patient was asymptomatic for bacterial vaginosis and Urinary tract infection.

On day II, specimens such as vaginal swab (1no) and urine in a sterile container came to the Microbiology section of District Public health laboratory, Government General Hospital of this region. After sample collection, patient was started with Taxim O 200mg for 3days and Metrogyl 400mg BD for 2 days.

On the same day, direct smear of Vaginal swab with Gram staining showed the presence of plenty of clue cells. These are vaginal epithelial cells having indistinct border due to the studding of Gram variable coccobacilli with absence of inflammatory cells (Figure 1 A,B). Only thin grey homogenous fluid was noted during vaginal swab collection and other tests of Amsel's criteria were not performed. With the Gram-stained vaginal smear, a Nugent score of 7 was obtained.⁷ Urine direct smear with Gram staining showed plenty of pus cells with Gram positive cocci in pairs, short and long chains and Gram-Negative bacilli.

Subsequently, vaginal swab was inoculated on blood and MacConkey agar and incubated aerobically at 37°C overnight. Semiquantitative culture of Urine was done on Cysteine lactose electrolyte deficient (CLED) agar by using standard bacteriological loop (0.1mL).⁸ After inoculation, plate was incubated at 37°C overnight aerobically. Next day, Vaginal swab culture on blood and MacConkey agar showed four different morphotypes of colonies. On Gram

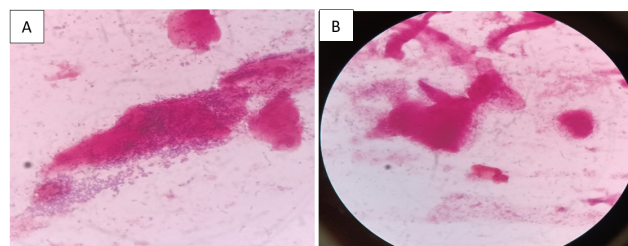


Fig. 1: Gram stain (Day-II) of Vaginal smear showing vaginal epithelial cells studded with gram variable bacilli (clue cells) from two different fields]

staining of each colony morphotype showed Gram positive cocci in groups, Gram Positive cocci in pairs and chains, Gram positive bacilli and Gram-negative bacilli. Further, processing of colonies was not done as it all resemble more of vaginal microbiota.

Urine culture with two different morphotypes of lactose fermenter (LF) with a count of $> 10^5$ CFU/mL was noted. On Gram staining, tiny LF was Gram positive cocci (GPC) in pairs and small LF was Gram negative bacilli (GNB). On further processing, GPC was catalase and bile esculin positive and identified as *Enterococcus spp.* GNB was Indole negative, Citrate positive, Urease negative and Triple sugar iron with A/A+, H₂S+ and identified as *Citrobacter freundii*. Antibiotic susceptibility testing was carried out with Mueller Hinton agar by Kirby Bauer disc diffusion method.⁹ The *Enterococcus spp* was sensitive to Ciprofloxacin, Vancomycin, Linezolid and resistant to Ampicillin and Penicillin whereas *C.frendii* was sensitive to Ampicillin, Cefotaxime, Cefixime, Cefuroxime, Ciprofloxacin, Meropenem and resistant to Amikacin. Blood specimen was not collected to detect coinfection with other agents such as Syphilis, Toxoplasmosis or viruses using TORCH panel.

On day III, threatened abortion progresses towards spontaneous miscarriage with expulsion of male foetus was noted. A second sample of Vaginal swab and Urine were also collected on day IV of admission. Gram-stained vaginal smear showed normal vaginal epithelial cells with devoid of bacteria (Figure 2) and Urine Gram stain showed absence of pus cells and bacteria with no growth on culture for both. On the same day, patient was discharged.

3. Discussion

The urogenital microbiota dominated by *Lactobacillus spp*, play a major role in maintenance of homeostasis and modulate the immune response. This contributes not only for female urogenital health but also for materno-foetal health in healthy pregnancies. Imbalance in vaginal microbiota can occur due to daily coitus, smokers, with a previous sexually transmitted disease or with high alcohol consumption in pregnant women. Such vaginal microbiota

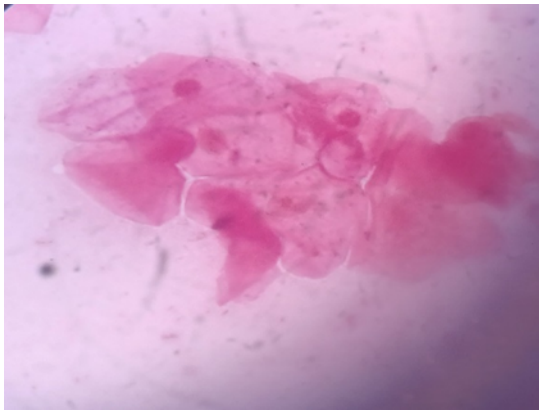


Fig. 2: Gram stain (Day-IV) of Vaginal smear showing intact vaginal epithelial cells with devoid of bacteria after treatment]

dysbiosis leads to bacterial vaginosis where in there is a loss of normally protective *Lactobacillus spp.* At the same time, there is increase in *Gardnerella vaginalis* which could harbor some uropathogenic strains to favor the colonization and might cause UTI.¹⁰ The co-existence of BV with UTI might result in adverse pregnancy outcomes like late miscarriage, preterm labor, low-birth weight infants, chorioamnionitis, postpartum endometritis and postabortion pelvic inflammatory disease.⁴

In the present case, woman in her II trimester came to casualty and on examination, the provisional diagnosis of threatened abortion was made on day I of admission. To identify the association of any infectious etiology, vaginal swab and urine specimen were sent to Microbiology laboratory on day II. Gram staining of vaginal smear showed the presence of clue cells and Nugent score of 7, which are suggestive of bacterial vaginosis. It is a gynaecological condition with decrease in number of *Lactobacillus spp* and proliferation of harmful bacteria such as *Gardnerella vaginalis*, *Prevotella spp*, *Bacteroides spp*, *Mobiluncus spp* and *Mycoplasma hominis* resulting in elevated pH. In this vaginal microbiota dysbiosis, the clinical presentation can be tested using Amsel's criteria.⁷ It includes the presence of thin greyish homogenous vaginal fluid with vaginal pH >4.5 on litmus paper test. On adding KOH to vaginal discharge gives fishy odour. The presence of clue cells can be detected by wet mount or Gram stain preparation. The diagnosis of bacterial vaginosis based on Amsel's criteria consist of three out of four test positive. In the present case, presence of thin grey homogenous fluid on collection of vaginal swab and presence of clue cells were noted and other tests of Amsel's criteria were not carried out due to insufficient specimen collection. Another method of BV diagnosis is based on a morphotype scoring system using Gram-stained vaginal smears called Nugent scoring method and in the present case scoring of 7 indicates bacterial vaginosis. The causative agents of bacterial vaginosis could not be isolated due to the

fastidious nature of the organism with different incubatory condition.

Due to the adverse outcomes, pregnancy with BV should be given much attention. In addition, such cases are also prone to UTI for which several reasons are put forth in few studies.^{3,4,11} It was explained that healthy vaginal microenvironment carrying predominant *Lactobacillus spp* provide protection against uropathogens through competitive adherence to uroepithelial cells. Therefore, *Lactobacillus spp* of vagina provides protection not only to female genital tract but also urinary tract through production of lactic acid, bacteriocins, surfactants, H₂O₂ and other antimicrobial products.

The present case was asymptomatic for not only bacterial vaginosis but also for urinary tract infection. The urine direct smear was suggestive of significant bacteriuria with growth of *Enterococcus spp* and *C.frendii* by semiquantitative culture method using CLED media. It has been put forth, that vaginal microbiota might influence host susceptibility to UTI. Studies also reported the coexistence of BV with UTI in pregnant women and stated an existence of 2.2- to 13.7-fold increased risk for UTI among women with BV in pregnant women.^{5,11} In the present study, the isolation of *Enterococcus spp* along with *C.frendii* from UTI might involve a synergetic relationship. It has been evident with the study where coinfections with *Enterococcus faecalis* modulate the local environment with secretion of L-ornithine that stimulate the growth and survival of *Escherichia coli* biofilm under iron limiting conditions.¹² Another study explains when the possible risk factors favour the condition of dysbiosis in women, the proliferation of facultative anaerobe *Gardnerella vaginalis* on vaginal epithelium forms a biofilm. This scaffolding helps the adherence of other bacteria in symbiotic fashion. Such polymicrobial environment allows the colonization of vaginal introitus and periurethral tissue with *E.coli* from dormant intracellular reservoirs in bladder to develop UTI through the induction of apoptosis and interleukin 1-receptor-mediated injury in bladder epithelial cells.¹⁰ The pathogenesis of UTI in such condition is driven by imbalance in urinary microbiota repertoire rather than an invasion by an exogenous pathogenic organism.

The vaginal metabolome studies also supported the existence of great variation in the composition of vaginal metabolites due to change in the bacterial communities. In the healthy vagina of pregnant women, higher levels of metabolites such as leucine, serine, phenylpropionate, isoleucine, and tryptophan are present whereas higher concentrations of putrescine, 2-hydroxyisovalerate, malonate, trimethylamine (TMA), tyramine, and acetate were the most significant metabolites of BV.^{13–15}

In the present case, pregnancy in woman could have been associated with physiological events like increased sex hormone levels, host immune response modulation, altered

immune-physicochemical properties of the cervical mucus, which could have driven changes in the structure and/or composition of the microbial community resulting in a vaginal microbiota dysbiosis. Moreover, the woman in the present study falls in the active reproductive age group and the possible sexual exposure could have also resulted in vaginal microbiota dysbiosis followed by UTI. One study reported around 88% of pregnant women of III trimester in the age group of 20-29 were found to have bacterial vaginosis whereas 41.8% are BV with asymptomatic UTI.⁶ The study also suggested the possible linkage between dysbiosis of vaginal microbiota and the dysbiosis of bladder microbiota.

On day III, the present case of threatened abortion progressed towards spontaneous miscarriage and the risk factor is BV with UTI. Spontaneous miscarriage is the pregnancy loss before 20 weeks of gestation without medical or mechanical means to terminate. The possible risk factors for spontaneous abortion includes chromosomal abnormalities, or maternal health before pregnancy like diabetes, thyroid, extreme weight, use of tobacco products, alcohol or illicit drugs, or structural abnormalities of uterus, or exposure to teratogens or infections during early pregnancy. In India, spontaneous miscarriage was observed in the age group of 23-27 years with the prevalence of 10%¹⁶ to 32%.¹⁷ It was also reported that 15% of early miscarriage and 66% late miscarriage are attributed to infections¹⁸ and also stated that women whose pregnancy resulted in miscarriage are at high risk of second pregnancy miscarriage.¹⁹ Studies have shown reduced prevalence of *Lactobacillus spp* and increased presence of several bacteria such as *Fam_Finegoldia*, *Lac_Coprococcus_3*, and *Lac_Roseburia* were found in most cases of spontaneous abortion during I trimester miscarriage.^{13,14} Moreso, increased concentration of specific metabolites like fumarate, ethanolamine in the vaginal environment have been recognized as BV-associated metabolites.¹⁵

4. Conclusion

The present study revealed the alteration in the microecology of vaginal microbiota leading to BV in pregnant women associated with asymptomatic UTI resulted in poor pregnancy outcome. The prevention of BV and UTI with antibiotics or probiotic intervention is a cost-effective measure to reduce the adverse outcomes in pregnancy and promotes healthy vaginal environment. Therefore, surveillance initiatives in antenatal health care facility among pregnant women for BV and UTI will help in lowering the severe maternal morbidity.

5. Source of Funding

None.

6. Conflict of Interest

None.

References

- Işık G, Demirezen Ş, Dönmez HG, Beksaç MS. Bacterial vaginosis in association with spontaneous abortion and recurrent pregnancy losses. *J Cytol*. 2016;33(3):135–40.
- Thomas-White K, Forster SC, Kumar N, Kuiken MV, Putonti C, Stares MD, et al. Culturing of female bladder bacteria reveals an interconnected urogenital microbiota. *Nat Commun*. 2018;9(1):1557.
- Kroon SJ, Ravel J, Huston WM. Cervicovaginal Microbiota, Women's Health, and Reproductive Outcomes. *Fertil Steril*. 2018;110(3):327–36.
- Gottschick C, Deng ZL, Vital M, Masur C, Abels C, Pieper DH, et al. The urinary microbiota of men and women and its changes in women during bacterial vaginosis and antibiotic treatment. *Microbiome*. 2017;5(1):99.
- Lata I, Pradeep Y, Sujata, Jain A. Estimation of the Incidence of Bacterial Vaginosis and other Vaginal Infections and its Consequences on Maternal/Fetal Outcome in Pregnant Women Attending an Antenatal Clinic in a Tertiary Care Hospital in North India. *Indian J Community Med*. 2010;35(2):285–9.
- Bhavana AM, Kumari PHP, Mohan N, Chandrasekhar V, Vijayalakshmi P, Manasa RV. Bacterial vaginosis and antibacterial susceptibility pattern of asymptomatic urinary tract infection in pregnant women at a tertiary care hospital, Visakhapatn, India. *Iran J Microbiol*. 2019;11(6):488–95.
- Udayalaxmi, Bhat G, Kotigadde S, Shenoy S. Comparison of the Methods of Diagnosis of Bacterial Vaginosis. *J Clin Diagn Res*. 2011;5(3):498–501.
- Collee JG, Fraser AG, Marmion BP, Simmons A. Mackie & McCartney Practical Medical Microbiology. 14th ed. New York: Churchill Livingstone; 1996.
- Performance Standards for Antimicrobial Susceptibility Testing. 31st ed. USA: Clinical and Laboratory Standards Institute; 2021.
- Gilbert NM, O'brien VP, Lewis AL. Transient microbiota exposures activate dormant *Escherichia coli* infection in the bladder and drive severe outcomes of recurrent disease. *PLoS Pathog*. 2017;13(3):e1006238.
- Sumati AH, Saritha NK. Association of urinary tract infection in women with bacterial vaginosis. *J Glob Infect Dis*. 2009;1(2):151–2.
- Keogh D, Tay WH, Ho YY, Dale JL, Chen S, Umashankar S, et al. Enterococcal Metabolite Cues Facilitate Interspecies Niche Modulation and Polymicrobial Infection. *Cell Host Microbe*. 2016;20(4):493–503.
- Al-Memar M, Bobdiwala S, Fourie H, Mannino R, Lee YS, Smith A, et al. The association between vaginal bacterial composition and miscarriage: a nested case-control study. *BJOG*. 2020;127(2):264–74.
- Xu L, Huang L, Lian C, Xue H, Lu Y, Chen X. Vaginal microbiota diversity of patients with embryonic miscarriage by using 16S rDNA high-throughput sequencing. *Int J Genomics*. 2020;2020:1764959. doi:10.1155/2020/1764959.
- Vitali B, Cruciani F, Picone G, Parolin C, Donders G, Laghi L. Vaginal Microbiome and Metabolome Highlight Specific Signatures of Bacterial Vaginosis. *Eur J Clin Microbiol Infect Dis*. 2015;34:2367–76.
- Larsen EC, Christiansen OB, Kolte AM, Macklon N. New insights into mechanisms behind miscarriage. *BMC Med*. 2013;11:154.
- Patki A, Chauhan N. An Epidemiology Study to Determine the Prevalence and Risk Factors Associated with Recurrent Spontaneous Miscarriage in India. *J Obstet Gynaecol India*. 2016;66(5):310–5.
- Srinivas SK, Ma Y, Sammel MD, Chou D, McGrath C, Parry S, et al. Placental inflammation and viral infection are implicated in second trimester pregnancy loss. *Am J Obstet Gynecol*. 2006;195(3):797–802.
- Kashanian M, Akbarian AR, Baradaran H, Shabandoust SH. Pregnancy outcome following a previous spontaneous abortion

(miscarriage). *Gynecol Obstet Invest.* 2006;61(3):167–70.

D Jeyakumari, Professor and Head

Author biography

S. R. Swarna, Associate Professor

R Vidyameena, Chief Medical Officer

T Bharathi, Microbiologist

Cite this article: Swarna SR, Vidyameena R, Bharathi T, Jeyakumari D. Association between vaginal microbiota dysbiosis with asymptomatic UTI in pregnant woman and adverse pregnancy outcome- A case report. *Indian J Microbiol Res* 2022;9(4):299-303.