



Case Report

Severe gastrointestinal cytomegalovirus infection with underlying common variable immunodeficiency in a middle aged lady

Dipankar Pal^{1,*}, Rajiv Karthik K¹

¹Dept. of Infectious Diseases, Christian Medical College, Vellore, Tamil Nadu, India



ARTICLE INFO

Article history:

Received 04-06-2023

Accepted 08-08-2023

Available online 10-10-2023

Keywords:

Cytomegalovirus

Gastrointestinal disease

Common variable immunodeficiency

ABSTRACT

Cytomegalovirus is a common herpes virus infection found worldwide and by adulthood majority become seropositive. In immunosuppressed state it may reactivate to cause tissue invasive disease in gastro intestinal tract, liver, lungs, brain and retina with or without viremia. It is commonly seen in bone marrow transplant, organ transplant, AIDS and autoimmune disease requiring intense immunosuppressive therapy. Common variable immunodeficiency is a condition that affects both arms of the immune system and can lead to opportunistic infections. Chance is more when CD4 counts falls below 50 cells/microlit.

This is an Open Access (OA) journal, and articles are distributed under the terms of the [Creative Commons Attribution-NonCommercial-ShareAlike 4.0 License](#), which allows others to remix, tweak, and build upon the work non-commercially, as long as appropriate credit is given and the new creations are licensed under the identical terms.

For reprints contact: reprint@ipinnovative.com

1. Introduction

Gastrointestinal cytomegalovirus infection most commonly involves colon followed by gastric antrum.¹ Symptomatic gastric CMV disease most commonly involves antrum causing antral gastritis and thickening of the pylorus.² It may lead to gastric outlet obstruction in extreme cases. Gastro intestinal CMV may manifest with or without detectable viremia.³ Gastric wall thickening and loco-regional lymphadenopathy can be detected by contrast enhanced CT abdomen.³ Extensive mucosal involvement may lead to malabsorption and hypoalbuminemia causing edema and third space fluid collection. It may manifest as localised gastrointestinal disease or can involve other organs in the background of CMV viremia.

Common variable immunodeficiency is the most frequently found symptomatic primary immunodeficiency in adults.⁴ Severity is variable and depends upon degree of immunosuppression. Phenotypically it may manifest as recurrent minor infections in some to more severe and recurrent infection in others. Therefore, the presentation

is heterogenous in nature. As cell mediated immunity is involved, there is increased chance of viral reactivation and infection with intra cellular bacteriae.

2. Case Report

A fifty-three-year old lady from North east India without any apparent comorbidity presented with gradually progressive abdominal distension and intermittent diarrhoea for three months. It was associated with post prandial abdominal fullness and vomiting. She lost seven kg body weight in three months and also had loss of appetite. Her symptoms were not accompanied with fever, pain abdomen, hematemesis, malena, joint pain or rash. She had no significant past medical or surgical history. She was neither diagnosed with tuberculosis never received any anti tubercular therapy in past. There was no history of contact with known case of open pulmonary tuberculosis.

Initially she was evaluated in her hometown where gastroscopy was done which showed probable ulcero-proliferative lesion in the gastric antrum. She came to our institute for further evaluation. During presentation, she was pale and non-icteric. There was no palpable lymph

* Corresponding author.

E-mail address: dipankarpal.2009@gmail.com (D. Pal).

node. Bipedal pitting edema was found. Neck veins are not engorged and she was hemodynamically stable. On systemic examination, she was found to have moderate ascites without organomegaly. Other systems were normal on examination.

Hemogram	Values	LFT	Values	Ascitic fluid	Values
Hb	8.59	Total bilirubin	0.65	Cell count	60
TLC	3400	Direct	0.27	N/L/E	48/48/4
N/L/M/E/B	89/5/5/1/0	Total protein	4.0 *	Protein	0.4
Platelets	1.98L	Albumin	1.8 *	SAAG	1.0
		SGOT	21	Glucose	97
		SGPT	18		
		ALP	154		

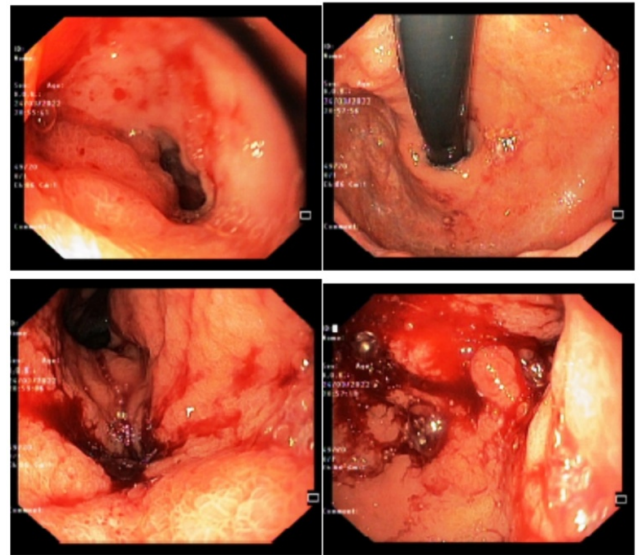


Fig. 1: Gastroscopy showing erythematous inflammaed antrum with narrowing

Baseline blood tests and ascitic fluid analysis were shown above. Repeated cytospin was negative for malignant cells from ascitic fluid. Blood borne virus screen was negative. Blood sugar was normal. Echocardiography showed normal ejection fraction with no regional wall motion abnormality. Chest x-ray showed minimal pleural effusion. Ultrasound abdomen and fibroscan did not reveal evidence of chronic liver disease. Doppler ultrasound showed no evidence of veno-occlusive disease including Budd-chiari syndrome. CT thorax and abdomen revealed thickening of lower half of stomach with loss of surrounding fat plane and loco-regional lymphadenopathy. The differentials considered in her were gastric malignancy, lymphoma, disseminated tuberculosis, gastrointestinal viral infections and chronic malabsorption syndrome.

Gastroscopy was performed which revealed multiple superficial antral ulcers with erythematous friable mucosa which bleeds on touch, narrowed gastric outlet and first part of duodenum.(Figure 1) Multiple biopsies were taken from antral mucosa which revealed gastritis with extensive inflammatory cell infiltrate and CMV inclusion bodies (Figure 2). Immunohistochemistry was done from the biopsy sample which showed eosinophilic inclusion body suggestive of cytomegalovirus (Figure 3).

As CMV antral gastritis was detected we evaluated further to look for evidence of CMV disease in other potential organs systems. There was no evidence of CMV retinitis. Serum CMV PCR was negative. CMV IgG & IgM were positive and negative respectively. Colonoscopy was performed which showed colonic ulcers and histopathology in addition to immunohistochemistry was suggestive of invasive CMV disease. Bone marrow examination showed normal trilineage hematopoiesis and no evidence of CMV infection. As we found extensive tissue invasive cytomegalovirus disease involving gastrointestinal

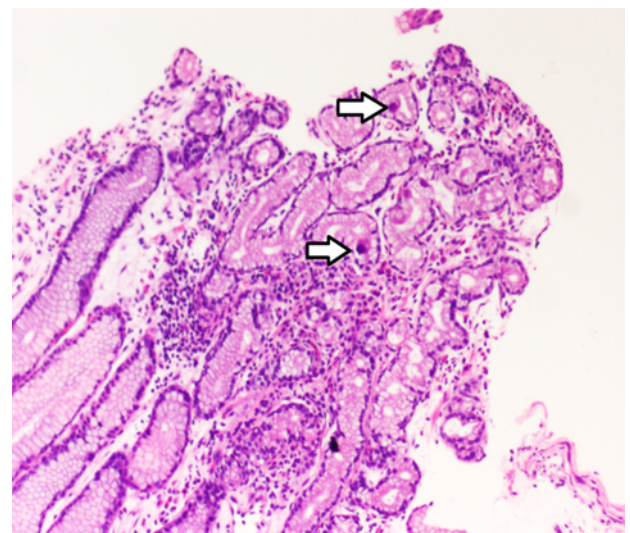


Fig. 2: Gastric antral biopsy showing chronic gastritis with extensive inflammatory cell infiltrate and CMV inclusion bodies (H & E stain : 100x)

tract; we ruled out other opportunistic infections with serum cryptococcal antigen. Gene Xpert from bone marrow, gastric tissue, sputum all were negative. Gene Xpert from gastric and colonic biopsy were also negative.

She was started on intravenous ganciclovir with careful monitoring of blood counts. She started showing response with improved food intake, reduced obstructive symptoms. Treatment was interrupted by severe leucopenia and her counts were recovered with G-CSF injection. She completed three weeks of therapy and switched over to oral valganciclovir. During discharge her hemoglobin was

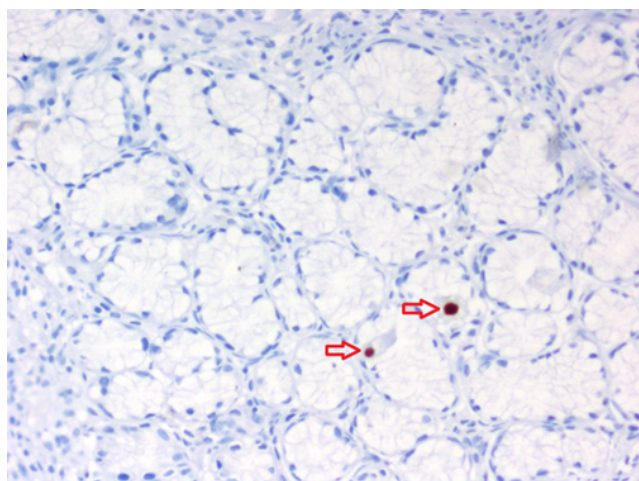


Fig. 3: Immunohistochemistry showing eosinophilic inclusion body suggestive of cytomegalovirus (200x)

improved, edema was settling with near normalization of serum albumin. Repeat gastroscopy at the end of three weeks showed improvement of antral gastritis.

We further evaluated her for possible immunodeficiency disorder as she developed extensive gastrointestinal cytomegalovirus invasive disease without any apparent state of immunosuppression. Her serum immunoglobulins were IgG- 639 (700-1600), IgA- 67 (70-400), IgM- 42 (40-230). CD4 count was 30 cells per microlit. T-lymphocyte subset analysis revealed diminished T cell, B cell, NK cells with gross age-specific lymphocytopenia. Vaccine response to her primary immunisation showed negative antibodies for polio, anti Hbs and MMR.

3. Discussion

She had gastrointestinal cytomegalovirus infection causing chronic antral gastritis. Persistent infection evolved into gastric outlet narrowing giving rise to obstructive symptoms.² It may mimic gastric malignancy in chronic cases. Upper gastrointestinal involvement is less common and the usual presentation is upper GI bleed. Commonset part involved is colon and when gastric tissue invasive CMV disease is detected other parts of gastro intestinal tract should also be screened. GI tract may be involved with or without CMV viremia as it used be secreted from mucosal epithelial cells in the absence of viremia.³ Such an extensive isolated GI involvement is seen less commonly.

CMV reactivation occurs when T cell specific immunity is diminished in host. CMV viremia often precedes invasive CMV disease in severely immunocompromised patients.⁵ CVID is the most common primary immunodeficiency found in adults.⁴ Its diagnosis depends upon ruling out other causes of immunodeficiency and involvement of both humoral and cellular arms.

3.1. The original ESID/PAGID (1999) criteria for probable and possible CVID⁶

3.1.1. Probable

3.1.1.1. Probable CVID. Male or female patient who has a marked decrease of IgG (at least 2 SD below the mean for age) and a marked decrease in at least one of the isotypes IgM or IgA, and fulfils all of the following criteria:

1. Onset of immunodeficiency at >2 years of age
2. Absent isohemagglutinins and/or poor response to vaccines
3. Defined causes of hypogammaglobulinemia have been excluded

3.1.1.2. Possible CVID. Male or female patient who has a marked decrease (at least 2 SD below the mean for age) in at least one of the major isotypes (IgM, IgG, and IgA) and fulfils all of the following criteria:

1. Onset of immunodeficiency at >2 years of age.
2. Absent isohemagglutinins and/or poor response to vaccines.
3. Defined causes of hypogammaglobulinemia have been excluded.

Simplified criteriae for diagnosis of Common Variable Immunodeficiency (CVID)

1. >2 years of age (usually presents in adolescents), Equal in both sexes.
2. Significantly reduced total IgG (mean-258).
3. Low IgM (40) and IgA (28).
4. Low CD4 T lymphocytes, adequate B lymphocytes; Plasma cells – low.
5. Poor vaccine response.
6. Absence of other immunodeficiency state.

In our case she had diminished serum immunoglobulins with markedly low CD4 T cells. Vaccine response assessment also revealed absent vaccine related antibodies. She was non diabetic and negative for HIV antibodies. She met the criteriae for CVID. Her CD4 cell count was only 30/microlit. Count less than 50/microlit is a well-known risk factor for CMV reactivation in AIDS.⁷ CMI is involved much more than humoral arm and that was the probable cause for CMV reactivation and subsequent extensive disease.

With CVID as an underlying immunocompromising condition, such an extensive gastrointestinal CMV disease is extremely rare in literature and worth reporting.⁸ CMV involving GI mucosa resulting into malabsorption and hypoalbuminemia is also rarely seen. It developed into low protein ascites and mimicked decompensated chronic liver disease in our case. Imaging of liver parenchyma and absence of varices ruled out chronic liver disease.

3.2. Patient Consent

Informed consent was taken from the patient for publication

4. Source of Funding

No funding was received from any organisation regarding this case.

5. Conflict of Interest


There is no conflict of interest with anybody or organisations.

References

1. Yeh PJ, Wu RC, Chiu CT, Lai MW, Chen CM, Pan YB, et al. Cytomegalovirus Diseases of the Gastrointestinal Tract. *Viruses*. 2022;14(2):352.
2. Beany A, Rainis T. CMV-Related Gastric Ulcer and Gastroduodenitis in an Immunocompetent Patient: A Case Report and Literature Review. *Case Rep Gastrointest Med*. 2021;2021:8604585. doi:10.1155/2021/3513223.
3. Chen D, Zhao R, Cao W, Zhou W, Jiang Y, Zhang S, et al. Clinical characteristics of cytomegalovirus gastritis: A retrospective study from a tertiary medical center. *Medicine (Baltimore)*. 2020;99(5):e18927. doi:10.1097/MD.00000000000018927.
4. Chen D, Zhao R, Cao W, Zhou W, Jiang Y, Zhang S, et al. Clinical characteristics of cytomegalovirus gastritis: A retrospective study from a tertiary medical center. *Medicine (Baltimore)*. 2020;99(5):e18927.
5. Ljungman P, Griffiths P, Paya C. Definitions of cytomegalovirus infection and disease in transplant recipients. *Clin Infect Dis*. 2002;34(8):1094–7.
6. Ameratunga R, Brewerton M, Slade C, Jordan A, Gillis D, Steele R, et al. Comparison of diagnostic criteria for common variable immunodeficiency disorder. *Front Immunol*. 2014;5:415. doi:10.3389/fimmu.2014.00415.
7. Nasa M, Sharma Z, Sud R, Lipi L. Cytomegalovirus infection of gastrointestinal tract. *Community Acquir Infect*. 2016;3(1):4–9.
8. Kralickova P, Mala E, Vokurkova D, Krcmova I, Pliskova L, Stepanova V, et al. Cytomegalovirus disease in patients with common variable immunodeficiency: three case reports. *Int Arch Allergy Immunol*. 2013;163(1):69–74.

Author biography

Dipankar Pal, Infectious Disease

Resident  <https://orcid.org/0009-0008-1486-5650>

Rajiv Karthik K, Associate Professor

Cite this article: Pal D, Karthik K R. Severe gastrointestinal cytomegalovirus infection with underlying common variable immunodeficiency in a middle aged lady. *Indian J Microbiol Res* 2023;10(3):177-180.