

Content available at: <https://www.ipinnovative.com/open-access-journals>

Indian Journal of Microbiology Research

Journal homepage: <https://www.ijmronline.org/>

Case Report

Pseudotumour of the penis: A rare clinical presentation of dirofilariasis first from South India

Viswaroop Sistla¹, Preethi Murthy², Ganesh Gopalakrishnan^{1*}

¹Vedanayagam Hospital and PG Institute, Tamil Nadu, India

²Laxmiram Biopsy Centre, Tamil Nadu, India



ARTICLE INFO

Article history:

Received 03-12-2023

Accepted 15-12-2023

Available online 27-12-2023

Keywords:

Pseudotumour

Nodule

Penis

Dirofilaria

ABSTRACT

Zoonotic helminthic infections are rare. They usually present as subcutaneous nodules in the upper part of the body mainly around the eyes and mouth. Genital involvement is uncommon with reports of *Dirofilariasis* of scrotum, epididymis and spermatic cord. We report a case of *Dirofilaria* infection presenting as a penile nodule in a young male from South India.

This is an Open Access (OA) journal, and articles are distributed under the terms of the [Creative Commons Attribution-NonCommercial-ShareAlike 4.0 License](https://creativecommons.org/licenses/by-nc-sa/4.0/), which allows others to remix, tweak, and build upon the work non-commercially, as long as appropriate credit is given and the new creations are licensed under the identical terms.

For reprints contact: reprint@ipinnovative.com

1. Introduction

Dirofilariasis is a zoonotic infection thought to be rare but increasing reports of human infection makes it an emerging zoonosis.¹ Of the 40 recognised species six are known to cause accidental infection in humans. The type of *Dirofilarial* species afflicting people varies with geographical area.² Based on the morphological and morphometric features Human *dirofilariasis* caused by three species, *D. repens*,^{3,4} *D. immitis*⁵ and *D. tenuis*⁶ have been reported from different parts of India.

Among the *Dirofilaria*, *D.repens* species presents as subcutaneous nodules mostly limited to upper trunk. Most commonly involved are face, conjunctiva of the eye, upper abdomen including chest wall, and arms. Male genital involvement can occur in form of pseudo tumour nodule affecting scrotum, epididymis and spermatic cord.⁷ We report first case of penile nodule presenting as a pseudotumor due to *D.repens* from South India.

2. Case Report

A 18-year-old male, college student from a coastal town in south Tamil Nadu was referred by a urology colleague for evaluation of a penile nodule. He noticed a small swelling 4 months ago while bathing and it was gradually increasing in size. The nodule was painless, and he had no itching or rashes. He has a pet dog at home but denies having any bite or scratchings. Clinically he had a 2 x 1.5cm ovoid, non-tender firm nodule with distinct margins, mobile transversely in the subcutaneous plane over dorsum of the penis about 3cm from coronal sulcus. Possibility of a benign tumour of neural origin was considered and MRI was done (Figure 1). It showed an ill-defined soft tissue lesion in the dorsal aspect of the penis over lying tunica albuginea and reported as nonspecific inflammatory lesion.

The nodule was excised under IV sedation and the biopsy was reported as helminthic infection morphologically as? *Ankylostoma* / *Dirofilaria* (Figure 2). He had no other lesions. He had no eosinophilia and his chest x-ray was normal. With further discussion with parasitologist we confirmed the diagnosis as *Dirofilaria*.

* Corresponding author.

E-mail address: ganeshgopalakrishnan@yahoo.com (G. Gopalakrishnan).

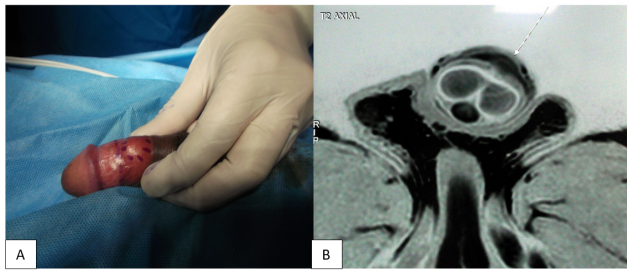


Figure 1: A): Nodule on the dorsum of the penis marked by methylene blue; B): MRI T2 phase axial section showing the nodule

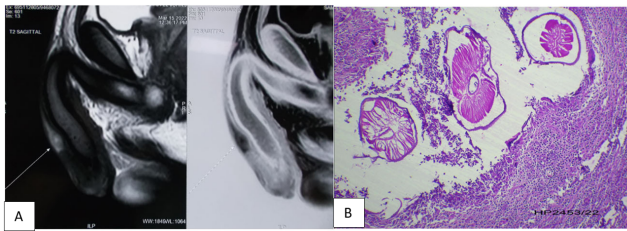


Figure 2: A): MRI coronal section of the T1 & T2 phase showing the lesion; B): HPE showing the helminthic worm with thick cuticle and muscle layer surrounded by abscess with inflammatory granulation tissue

3. Discussion

Zoonotic infections affecting humans are not uncommon. It is usually caused by *Ankylostoma* and presents as linear serpentine marks, folliculitis, or vesiculobullous lesions commonly known as creeping larvae migrans. These lesions are extremely itchy and associated with eosinophilia and rarely presents as a nodule.

Dirofilariasis is another zoonotic infection caused by filarial nematode of gene *Dirofilaria* of which *D.repens* is the most common being endemic in some parts of the world including our neighbouring country Srilanka. *Dirofilaria* infection naturally occurs in wild and domestic animal with canines as principal reservoir host. *Dirofilaria* causes accidental infection in humans with mosquitoes (*Aedes*, *Armigeres*, *Culex*, *Anopheles*, and *Mansonia*) as main vectors. The infected larva injected into the human by mosquito bites perishes without transforming to microfilaria hence person to person transmission does not occur.⁸

Human dirofilariasis manifests commonly as either subcutaneous nodules or lung infection. The pulmonary infection is usually asymptomatic with occasional symptoms of cough, chest pain, fever and pleural effusion. Subcutaneous nodules when occur are often tender and may be fixed or migratory. Subcutaneous lumps can manifest in various locations the most typical being in exposed sites (e.g. scalp, arms, legs, eyelids, chest), but occasionally have been found in deeper tissue such as the breast, epididymis, spermatic cord, and sub conjunctiva.⁸

Most of the cases reported from India are of ocular infections and very few have reported subcutaneous *Dirofilariasis*. But none of them were penile nodules. This is the first case of *Dirofilariasis* presenting as penile nodule from India and second in the world.⁹ In our case the lesion was dorsally located unlike, the ventrally located lesion in the only other case report.⁹ Because of the dorsal location of tumour, we had considered a possibility of a neural tumour and hence proceeded with MRI. Surgical excision and biopsy of the lesion is both diagnostic and treatment as in our case. As microfilaremia is extremely rare, routine use of systemic antimicrobial therapy is not indicated.²

The morphological examination has limitations especially in identifying exact species of *Dirofilaria* as many share same features as *D.repens*. Genetic analysis using mitochondrial and genomic DNA sequences help to confirm not only the species subtype but also establishes the phylogenetic tree with authenticity.¹⁰

4. Conclusion

Zoonotic infections in humans are common. Genital involvement is extremely rare and usually managed by dermatologists. This is a unique case of helminthic infection presenting as a nodule over shaft of the penis. Population having pets at home is on raise and should be considered when coming across unusual clinical presentations.

5. Source of Funding

None.

6. Conflict of Interest

None.

7. Acknowledgement

We would like to thank Dr. Raghuram Ganesamoni for the referral and Dr. Ammu nair for her inputs.

References

- Reddy MV. Human dirofilariasis: An emerging zoonosis. *Trop Parasitol.* 2013;3(1):2–3.
- Orihel TC, Eberhard ML. Zoonotic filariasis. *Clin Microbiol Rev.* 1998;11(2):366–81.
- Padmaja P, Kanagalakshmi, Samuel R, Kuruvilla PJ, Mathai E. Subcutaneous dirofilariasis in Southern India: A case report. *Ann Trop Med Parasitol.* 2005;99(4):437–40.
- Permi HS, Veena S, Prasad HLK, Kumar YS, Mohan R, Shetty KJ. Subcutaneous human dirofilariasis due to *Dirofilaria repens*: Report of two cases. *J Glob Infect Dis.* 2011;3(2):199–201.
- Badhe BP, Sane SY. Human pulmonary dirofilariasis in India: A case report. *J Trop Med Hyg.* 1989;92:425–6.
- Bhat KG, Wilson G, Mallya S. Human dirofilariasis. *Indian J Med Microbiol.* 2003;21:223.
- Pampiglione S, Rivasi F, Angeli G, Boldorini R, Incensati RM, Pastormerlo M, et al. Dirofilariasis due to *Dirofilaria repens* in Italy, an emergent zoonosis: report of 60 new cases. *Histopathology.* 2001;38(4):344–54.

8. Joseph E, Matthai A, Abraham LK, Thomas S. Subcutaneous human dirofilariasis. *J Parasit Dis.* 2011;35(2):140–3.
9. Stayerman C, Szvalb S, Sazbon A. *Dirofilaria repens* presenting as a subcutaneous nodule in the penis. *BJU Int.* 1999;84(6):746–7.
10. Najuma N, Bindu L, Jayavardhana KK. Molecular characterization of human *Dirofilaria* isolates from Kerala. *Indian J Med Res.* 2017;146(4):528–33.

Author biography

Viswaroop Sistla, Senior Consultant

Preethi Murthy, Senior Consultant

Ganesh Gopalakrishnan, Professor

Cite this article: Sistla V, Murthy P, Gopalakrishnan G. Pseudotumour of the penis: A rare clinical presentation of dirofilariasis first from South India. *Indian J Microbiol Res* 2023;10(4):246-248.