

Content available at: <https://www.ipinnovative.com/open-access-journals>

Indian Journal of Microbiology Research

Journal homepage: <https://www.ijmronline.org/>

## Case Report

# A case report on melioidosis

Aparna Rajeev<sup>1\*</sup>, Sushitha T Surendran<sup>1</sup>

<sup>1</sup>Dept. of Microbiology, Government Medical College, Kochi, Kerala, India



### ARTICLE INFO

#### Article history:

Received 15-05-2024

Accepted 21-06-2024

Available online 16-07-2024

#### Keywords:

*Burkholderia pseudomallei*

Melioidosis

Gram negative bacilli

### ABSTRACT

Melioidosis is a rare multi system involving infectious disease caused by *Burkholderia pseudomallei*. This case report is on a 60year old male patient who was presented with long history of intermittent fever. We reviewed literature on *Burkholderia pseudoGram Negative bacilli* and management.

This is an Open Access (OA) journal, and articles are distributed under the terms of the [Creative Commons Attribution-NonCommercial-ShareAlike 4.0 License](https://creativecommons.org/licenses/by-nc-sa/4.0/), which allows others to remix, tweak, and build upon the work non-commercially, as long as appropriate credit is given and the new creations are licensed under the identical terms.

For reprints contact: [reprint@ipinnovative.com](mailto:reprint@ipinnovative.com)

## 1. Introduction

*Burkholderia pseudomallei* is an environmental gram negative bacilli, nowadays which is considered as an emerging pathogen in India.<sup>1</sup> Melioidosis can present in various clinical forms such as septicemia, abscess of multiple organs, arthritis etc.<sup>2</sup> About 44% of global burden of melioidosis is seen in South Asia with endemicity in Bangladesh and Sri Lanka.<sup>1</sup> This infection is largely underdiagnosed in our country and also underreported due to its varied clinical presentation which accounts for it to be rare in India.<sup>1</sup> In India, most cases have so far been reported from the southern states like Kerela and Tamil Nadu.<sup>2</sup>

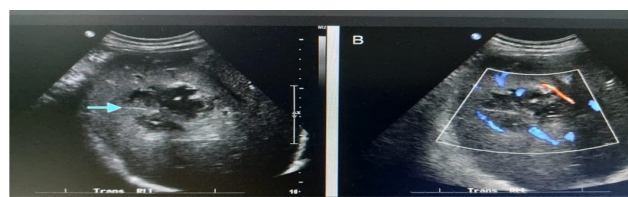
## 2. Case Report

A 60year old man from south Kerala who was a referred case from Taluk hospital got admitted in a tertiary care center in July 2022. He presented with Intermittent fever and myalgia for 14 days and was not on treatment for any comorbidities. Fever was associated with chills and fever spikes were more during the night time. Patient had complaints of vomiting associated with nausea and abdominal pain for 5 days. He also gave history of loss of

appetite, and fatigability. Patient got diagnosed with Type 2 diabetes mellitus (RBS-420mg/dl, HbA1C-7.4) after getting admitted in our hospital.

On examination patient was conscious, oriented, vitals were stable. Per abdominal examination showed mild hepatomegaly and splenomegaly. All other systemic examinations were normal. Routine investigations showed neutrophilic leukocytosis, elevated inflammatory markers (CRP-9.6mg/L). Liver function test was deranged. Hepatitis, dengue and leptospirosis were ruled out by serological tests.

USG abdomen and pelvis illustrated mild hepatomegaly with evolving abscess in the right lobe of liver and spleen also showed small multiple abscesses.

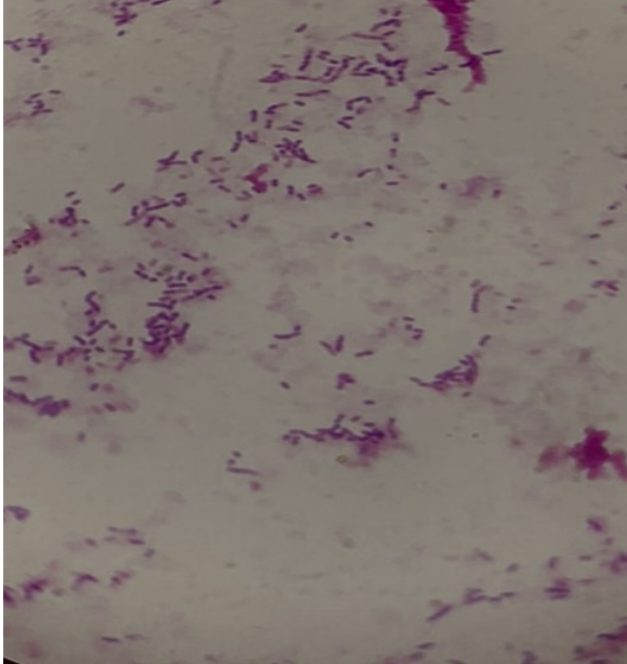


**Figure 1:** Image of USG abdomen showing multiple abscesses

\* Corresponding author.

E-mail address: [appus1289.rajeev@gmail.com](mailto:appus1289.rajeev@gmail.com) (A. Rajeev).

Blood was received for culture from the patient on the day of admission before starting antibiotics. Sample was inoculated into automated blood culture system (BacT/Alert). The blood culture bottle flagged signal positive on next day. Sample from this bottle was inoculated on Blood agar and MacConkey agar plates. Direct smear showed gram negative bacilli with bipolar staining or safety pin appearance.




**Figure 2:** Direct smear showing gram negative bacilli with bipolar staining

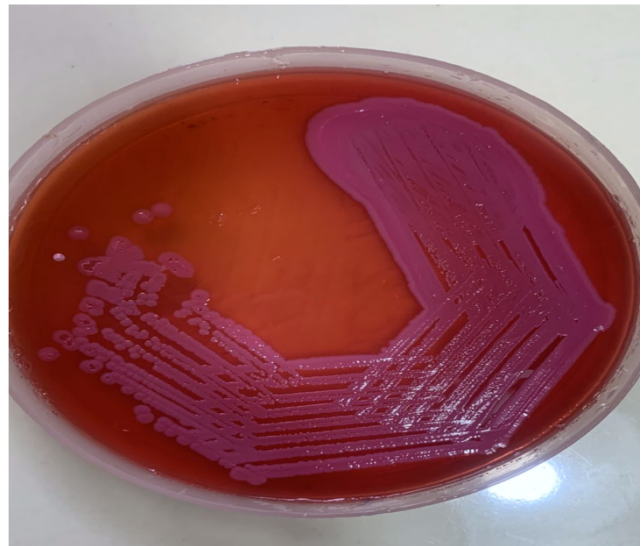
Both the culture plates were incubated at 37°C. After overnight incubation blood agar showed nonlytic greyish white colonies and MacConkey agar had shown non lactose fermenting colonies.

After 48 hours of incubation, blood agar plate showed grey wrinkled dry colonies and MacConkey agar showed pinkish dry wrinkled colonies with metallic sheen.

Identification was done by standard microbiological techniques that included gram-negative bacilli with bipolar staining, motile, growth on MacConkey's agar showing rough, wrinkled, pink coloured colonies with a metallic sheen, catalase positive, oxidase positive, indole negative, nitrate reducing, lysine decarboxylase negative, arginine dihydrolase positive. Automated identification was also performed using VITEK-2 Compact system, bioMerieux. In our case Antibiotic susceptibility testing was done by disc diffusion method and interpreted by European Committee on Antimicrobial Susceptibility Testing (EUCAST) guidelines, to guide the treatment. The isolate was susceptible to Ceftazidime, Cotrimoxazole, Doxycycline, Amoxicillin-clavulanic acid, Meropenem and



**Figure 3:** Blood agar showing growth after 48 hours of incubation



**Figure 4:** MacConkey agar plate showing growth after 48 hours of incubation

Imipenem Resistant to Gentamicin (10 µg) and polymyxin B (10 µg) was used to identify the organism.

On admission patient was given antibiotic injection ceftriaxone and doxycycline. After receiving our culture and sensitivity report the patient was started with Inj. Ceftazidime 2g IV 6<sup>th</sup> hourly for 4 weeks. Simultaneously blood sugar level was also controlled by insulin followed by oral hypoglycemic agents. After starting Ceftazidime injection patient became symptomatically better. He got discharged after 4 weeks with maintenance therapy with tablet Cotrimoxazole DS 960mg 12<sup>th</sup> hourly for 3 months.

### 3. Results

Patient presented with unexplained fever, Type 2 Diabetes mellitus and multiple abscesses in liver and spleen.

His blood culture yielded *B.pseudomallei* which was confirmed by VITEK2. He was managed with appropriate antimicrobial therapy. The patient got recovered and discharged.

#### 4. Discussion

*Burkholderia pseudomallei* presents as an environmental saprophyte in soil and fresh surface water in endemic regions.<sup>3</sup> The organism may be routinely isolated from environmental niches such as stagnant waters, moist soils and rice paddies.<sup>4</sup> Human infection occurs through inhalation or direct inoculation on damaged skin.<sup>2</sup> A recent study from southern Kerala indicated that both patients became ill during the monsoon season, when it rains heavily in Kerala. Studies have shown a correlation between the disease and rainfall intensity.<sup>5</sup> In our case the patient was from South Kerala, and he presented with his condition during the monsoon period also he was exposed to flood water, which could be the source of infection.

Diabetes mellitus (DM) has been found to be one of the most common predisposing factor. Vidyalakshmi et al. found out that 76% of melioidosis cases were diabetic in their study.<sup>6</sup> Active infection has been predisposed to occur in patients with many underlying risk factors such as DM, renal disease and HIV infection.<sup>2,7</sup> In our case, patient was an undetected case of Type 2 Diabetes mellites.

Clinical and laboratory Standards Institute (CLSI) M45 guidelines recommends only broth micro dilution method for antibiotic susceptibility testing of *B.pseudomallei*. This method is difficult to perform during routine diagnostics. The Vitec 2 compact system performs identification of *B.pseudomallei*; but the software database for analysis of the minimum inhibitory concentration (MIC) is unavailable so, to guide the treatment disc diffusion was performed by the EUCAST method.

Melioidosis is a systemic manifestation with pulmonary involvement as the commonest.<sup>2</sup> A recent study from India reported that frequent respiratory involvement and bacteraemia in adult cases.<sup>5</sup> Our patient had no pulmonary manifestations. Melioidosis entails febrile illness, abscess formation in the lung, liver, spleen and septicaemic features.<sup>8</sup> In our case patient had shown the same scenario of intermittent febrile episodes and evolving abscesses in liver and spleen.

This bacteria has a unique antibiotic susceptibility pattern. In addition to broad spectrum antibiotics like ceftazidime, carbapenems and cotrimoxazole; it is susceptible to amoxicillin-clavulanic acid and doxycycline. It has intrinsic resistance towards the aminoglycosides and colistin.<sup>9</sup> The drug of choice is ceftazidime in systemic melioidosis.<sup>2</sup> Ceftazidime resistance strains are treated with carbapenems.<sup>9</sup> In acute phase intravenous antibiotics preferably ceftazidime for 2- 8 weeks is recommended. Eradication phase regimen is oral antibiotics preferably cotrimoxazole and alternative is amoxicillin-clavulanic

acid. Duration of eradication phase is 3-6 months.<sup>9</sup> Our patient was put on with injection ceftazidime for 4 weeks, and he became symptomatically better. He was discharged with instructions to take oral cotrimoxazole for 3 months. Varied clinical presentation of melioidosis makes the clinical diagnosis difficult. An alert laboratory team, with suspicion of *B.pseudomallei* is required for early diagnosis. Lack of adherence to the treatment protocol can lead to reactivation.

#### 5. Sources of Funding

None.

#### 6. Conflict of Interest

None.

#### Acknowledgments

Dr Joana Mary Magdaline, Professor and Head, Department of Microbiology, Government Medical College, Ernakulam.

#### References

- Anuradha K, Meena AK, Lakshmi V. Isolation of *Burkholderia pseudomallei* from a case of septicaemia—a case report. *Indian J Med Microbiol.* 2003;21(2):129–32.
- Barman P, Sidhwa H, Shirkhande PA. Melioidosis: A case report. *J Glob Infect Dis.* 2011;3(2):183–6.
- Barman P, Kaur R, Kumar K. Clinically lesser known entity in India: A report of two cases of melioidosis. *Indian J Crit Care Med.* 2013;17(1):46–8.
- Brett PJ, Deshazer D, Woods DE. Characterization of *Burkholderia pseudomallei* and *Burkholderia pseudomallei*-like strains. *Epidemiol Infect.* 1997;118(2):137–48.
- Bhaskaran P, Prasad V, Gopinathan A, Shaw T, Sivadas S, Jayakumar C, et al. *Burkholderia pseudomallei* in Environment of Adolescent Siblings with Melioidosis, Kerala, India, 2019. *Emerg Infect Dis.* 2019;28(6):1246–9.
- Vidyalakshmi K, Lipika S, Vishal S, Damodar S, Chakrapani M. Emerging clinico-epidemiological trends in melioidosis: analysis of 95 cases from western coastal India. *Int J Infect Dis.* 2012;16(7):491–7.
- Mukhopadhyaya A, Balaji V, Jesudason MV, Amte A, Jeyamani R, Kurian G. Isolated liver abscesses in melioidosis. *Indian J Med Microbiol.* 2007;25(2):150–1.
- Saravu K, Vishwanath S, Kumar RS, Barkur AS, Varghese GK, Mukhyopadhyay C, et al. Melioidosis—a case series from south India. *Trans R Soc Trop Med Hyg.* 2008;102(Suppl 1):18–20.
- Sullivan RP, Marshall CS, Anstey NM, Ward L, Currie BJ. 2020 Review and revision of the 2015 Darwin melioidosis treatment guideline: paradigm drift not shift. *PLoS Negl Trop Dis.* 2020;14(9):e0008659.

#### Author biography

Aparna Rajeev, PG Resident

Sushitha T Surendran, Assistant Professor

Cite this article: Rajeev A, Surendran ST. A case report on melioidosis. *Indian J Microbiol Res* 2024;11(2):119-121.